



ABO Sample Cases (Part I)

(Rev. 03.01.2024)

Disclaimer

- The following sample questions and answers were composed and vetted by a panel of experts in orthodontics and are intended to provide a guide of the types of cases and questions that make up the actual Scenario-based Clinical Examination.
- After the examination, trained examiners, who are all in–good-standing board certified orthodontists, will score the typed responses using rubrics as guides to their decision making.
- Rubrics help to create consistency in the decisions the examiners make while grading an examinees typed responses. The rubrics are not absolute, as there may be other acceptable answers that are not listed. However, no credits will be awarded for answers not included in the rubrics.

Disclaimer Cont.

- The ABO has developed multiple versions of the case-based scenario examination to be used during a test administration cycle. Although the set of cases and questions used on the different versions will not all be the same, all versions follow the same content framework as defined by the practice analysis study.
- Scores will be computed using psychometric equating procedures to ensure that all versions are of the same difficulty level.
- Review of these sample cases does not guarantee that a candidate will pass the examination.
- Examinee responses to exam questions will be typed out and should be in numbered list format (i.e., short and concise, no essay responses).

Sample Case #1

Sample Case #1

Opening Scenario:

A 10-year, 8-month-old female has been referred by a dentist for an orthodontic evaluation. The mother's chief complaint is that her daughter "doesn't have room for all of her teeth."

Sample Case #1

Question 1

Classification

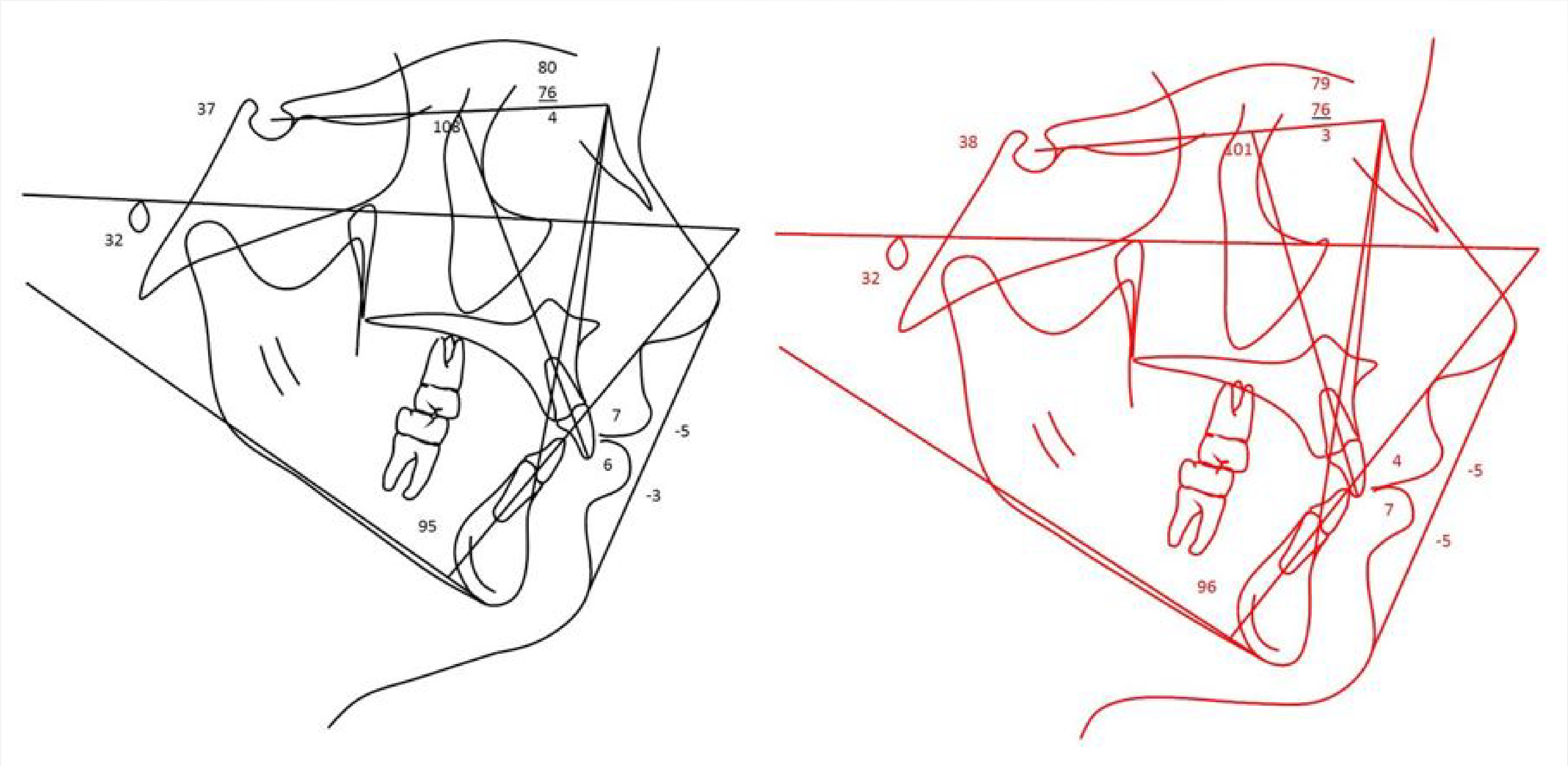
Domain 4: Critical Analysis and Outcomes Assessment

Prompt

Using the superimpositions, identify the dental changes that resulted from treatment (22 months treatment time). Please respond in numbered list format below.

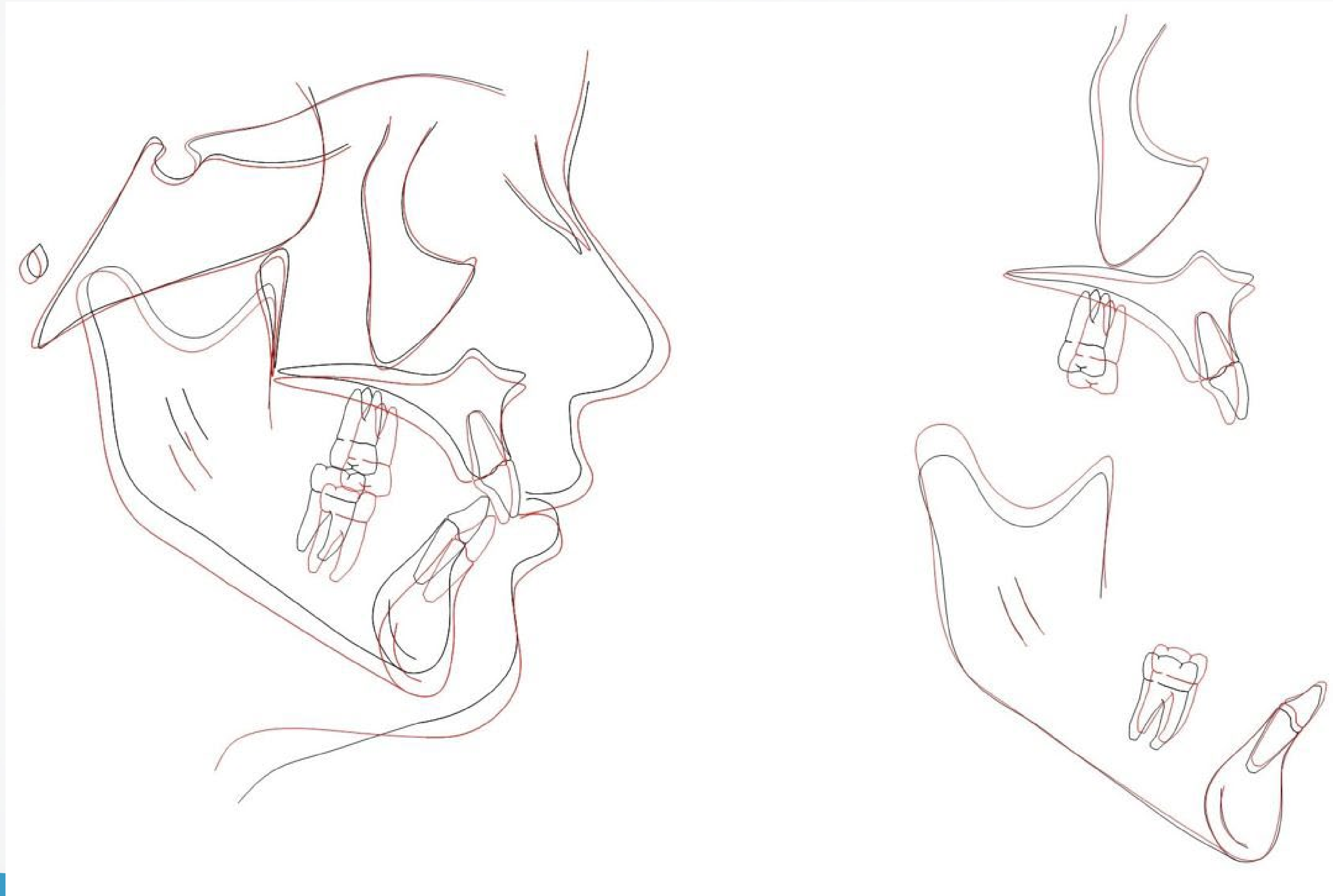
Sample Case #1

Question 1



Sample Case #1

Question 1



Sample Case #1

Question 1

Classification

Domain 4: Critical Analysis and Outcomes Assessment

Prompt

Using the superimpositions, identify the dental changes that resulted from treatment (22 months treatment time). Please respond in numbered list format below.

Sample Case #1

Question 1

Fully Proficient Model Response

The examinee's response must include five or more of the following:

1. Maxillary molars moved mesially
2. Maxillary molars extruded (accept slight extrusion)
3. Maxillary incisors retroclined
4. Maxillary incisors held vertically
5. Mandibular molars were held vertically
6. Mandibular incisors were held vertically

Sample Case #1

Question 1

Borderline Proficient Model Response

The examinee's response must include four of the above.

Not Proficient Model Response

The examinee's response includes three or fewer of the above.

Sample Case #2

Sample Case #2

Opening Scenario:

An 8-year, 10-month-old male has been referred by a dentist for an orthodontic evaluation of permanent tooth eruption. The mother's chief complaint is that "my son grinds his teeth at night."

Sample Case #2

Question 1

Classification

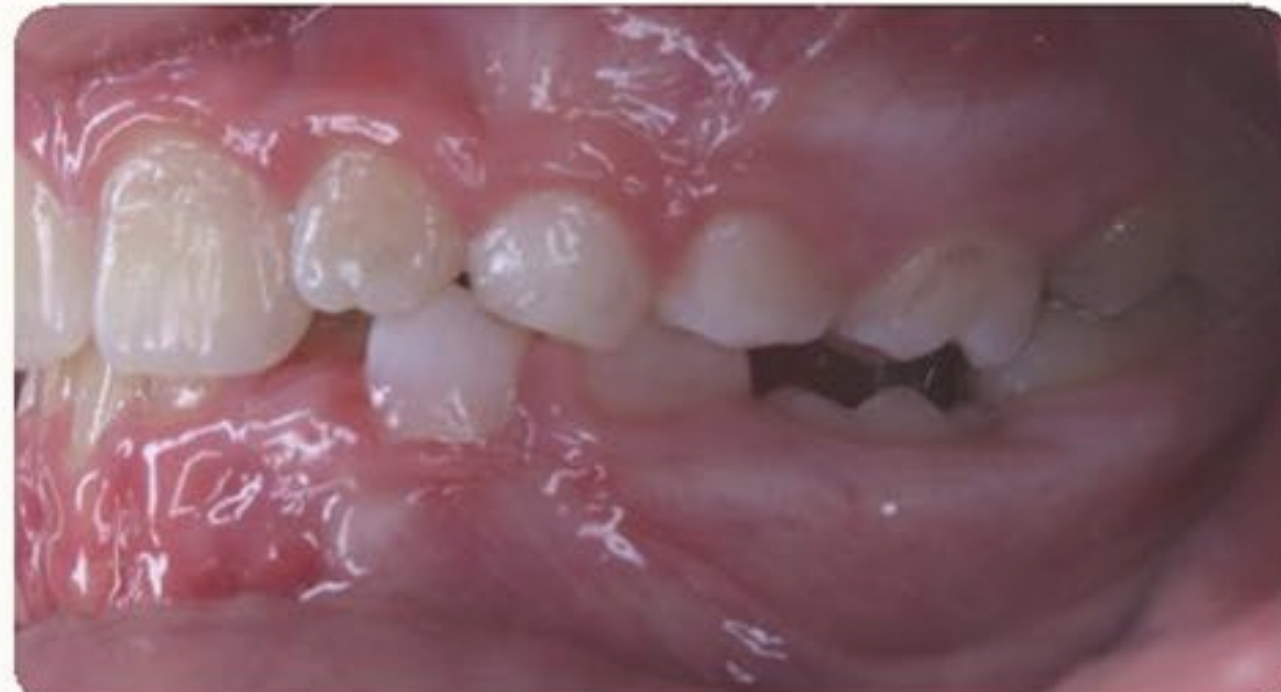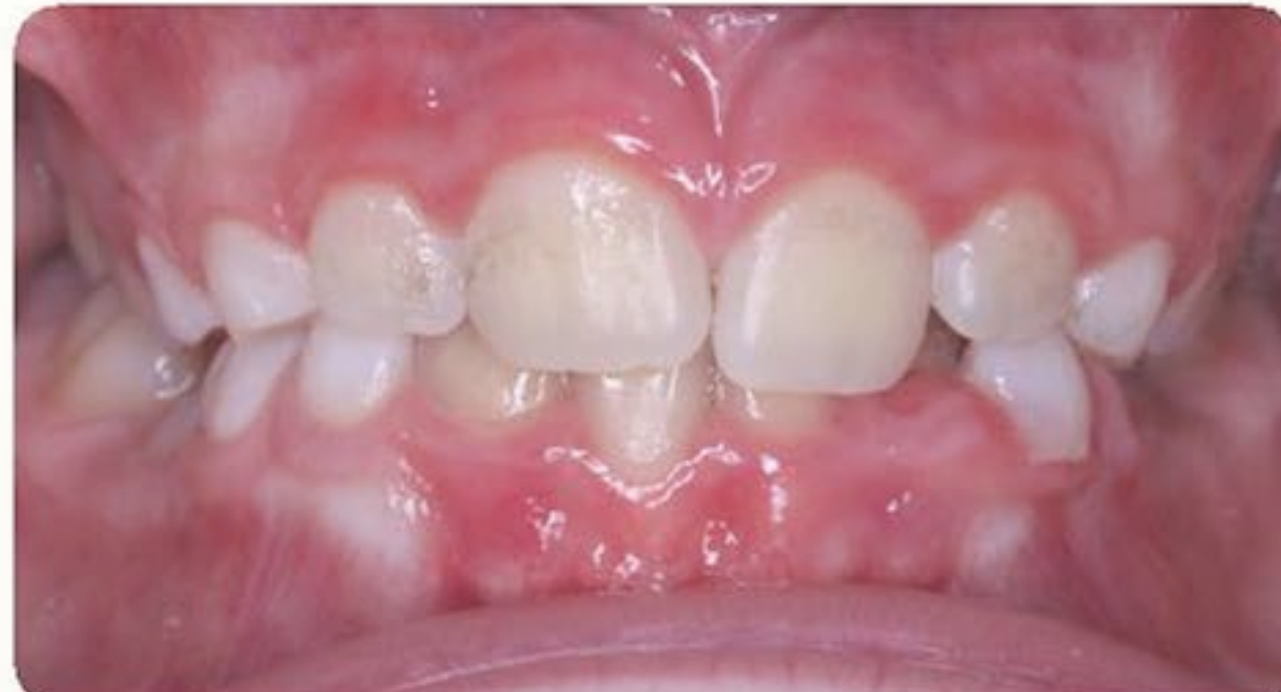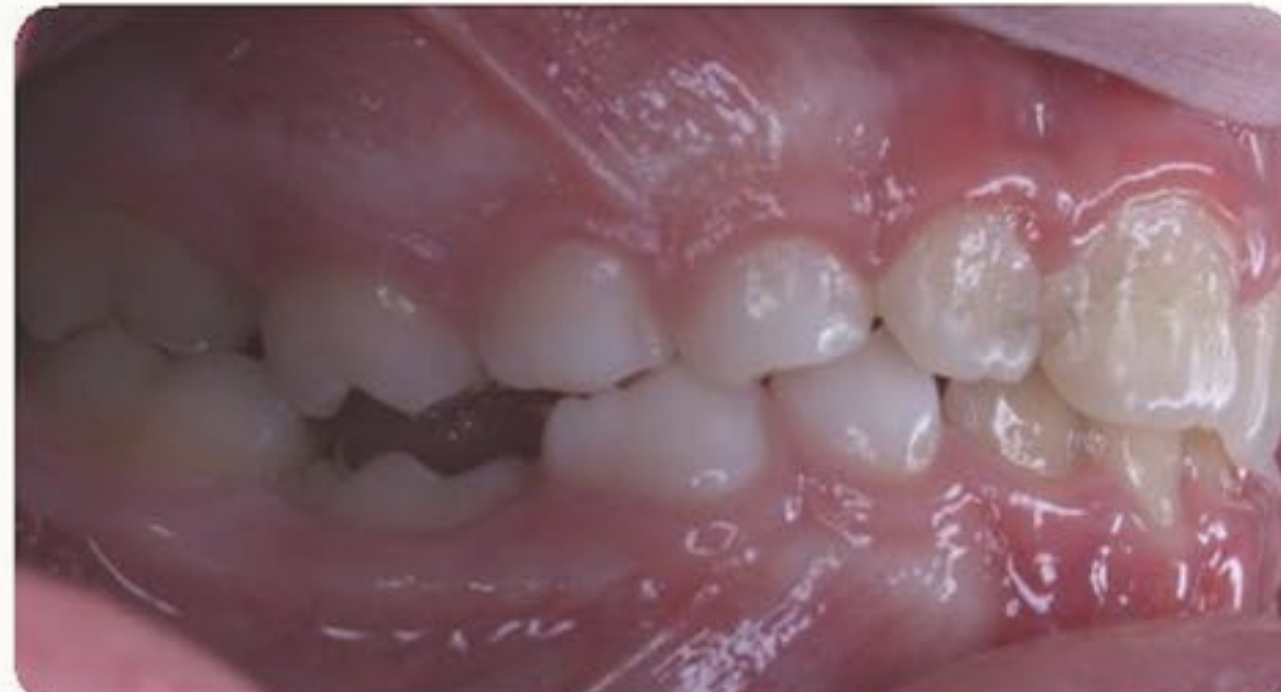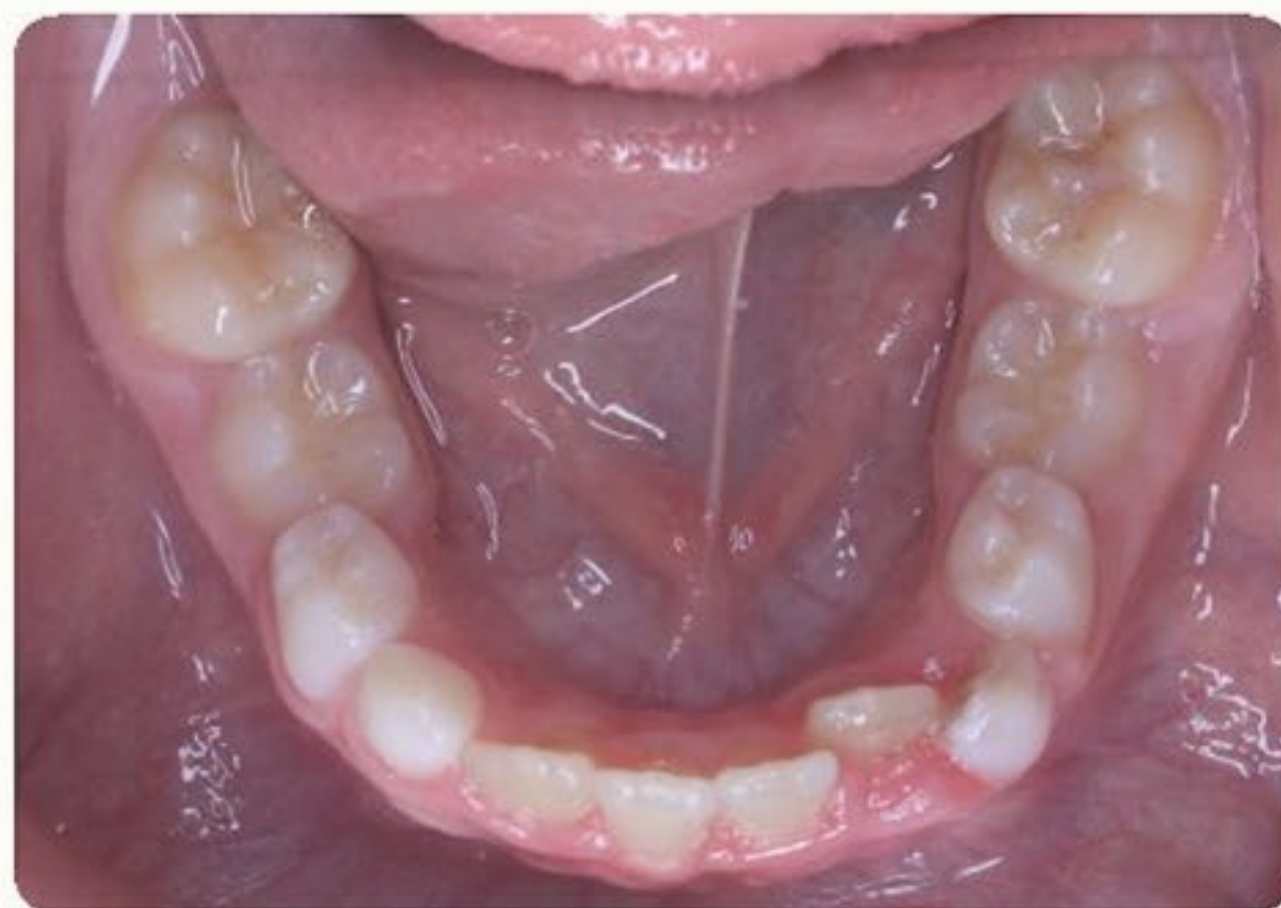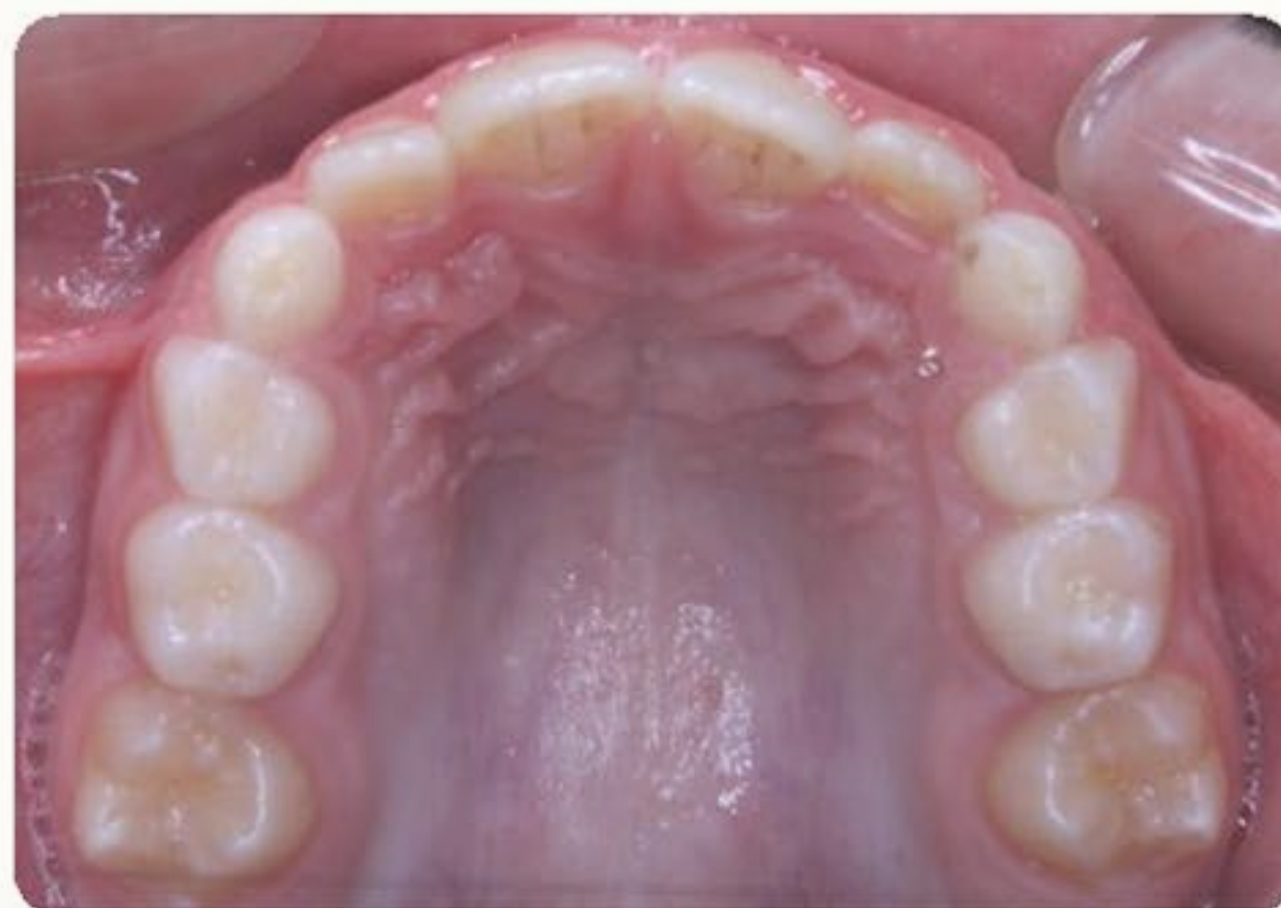Domain 1: Data Gathering and Diagnosis

Prompt

Identify all dental abnormalities evident in the intraoral photographs and the panoramic radiograph. Please respond in numbered list format below.

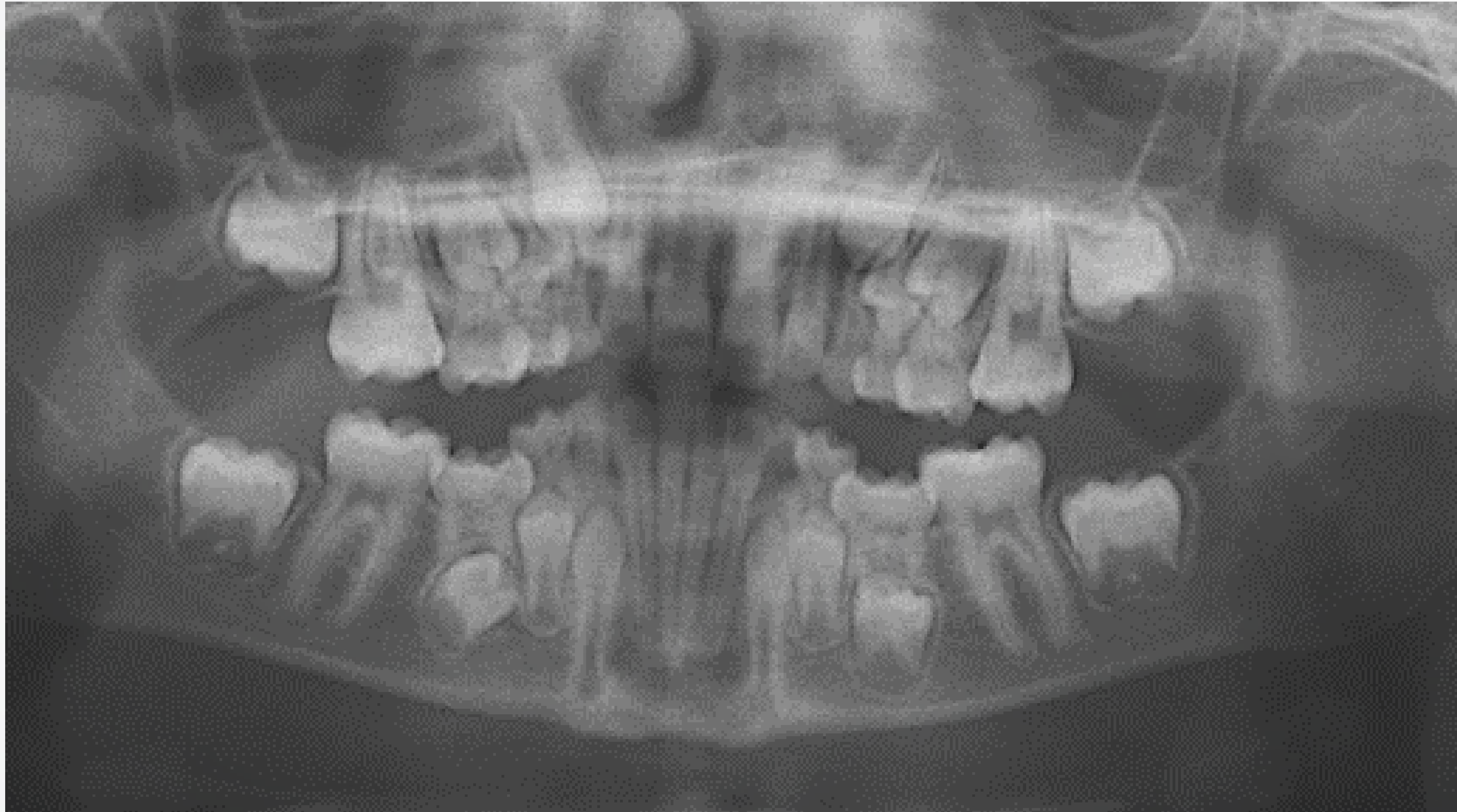
Sample Case #2

Question 1



Sample Case #2

Question 1



Sample Case #2

Question 1

Classification

Domain 1: Data Gathering and Diagnosis

Prompt

Identify all dental abnormalities evident in the intraoral photographs and the panoramic radiograph. Please respond in numbered list format below.

Sample Case #2

Question 1

Fully Proficient Model Response

The examinee's response must include six of the following:

1. Possible Ankylosis of the deciduous mandibular second molars (accept submerged)
2. Supra eruption of the maxillary second deciduous molars
3. Mesio-angulated mandibular right second premolar
4. Mesial tipping of the mandibular first molars
5. Mandibular anterior crowding with lingually displaced left lateral incisor
6. Reduced attach gingiva on the mandibular right central incisor
7. Deep overbite

Sample Case #2

Question 1

Borderline Proficient Model Response

The examinee's response must include five of the above.

Not Proficient Model Response

The examinee's response includes four or fewer of the above.

Sample Case #2

Question 2

Classification

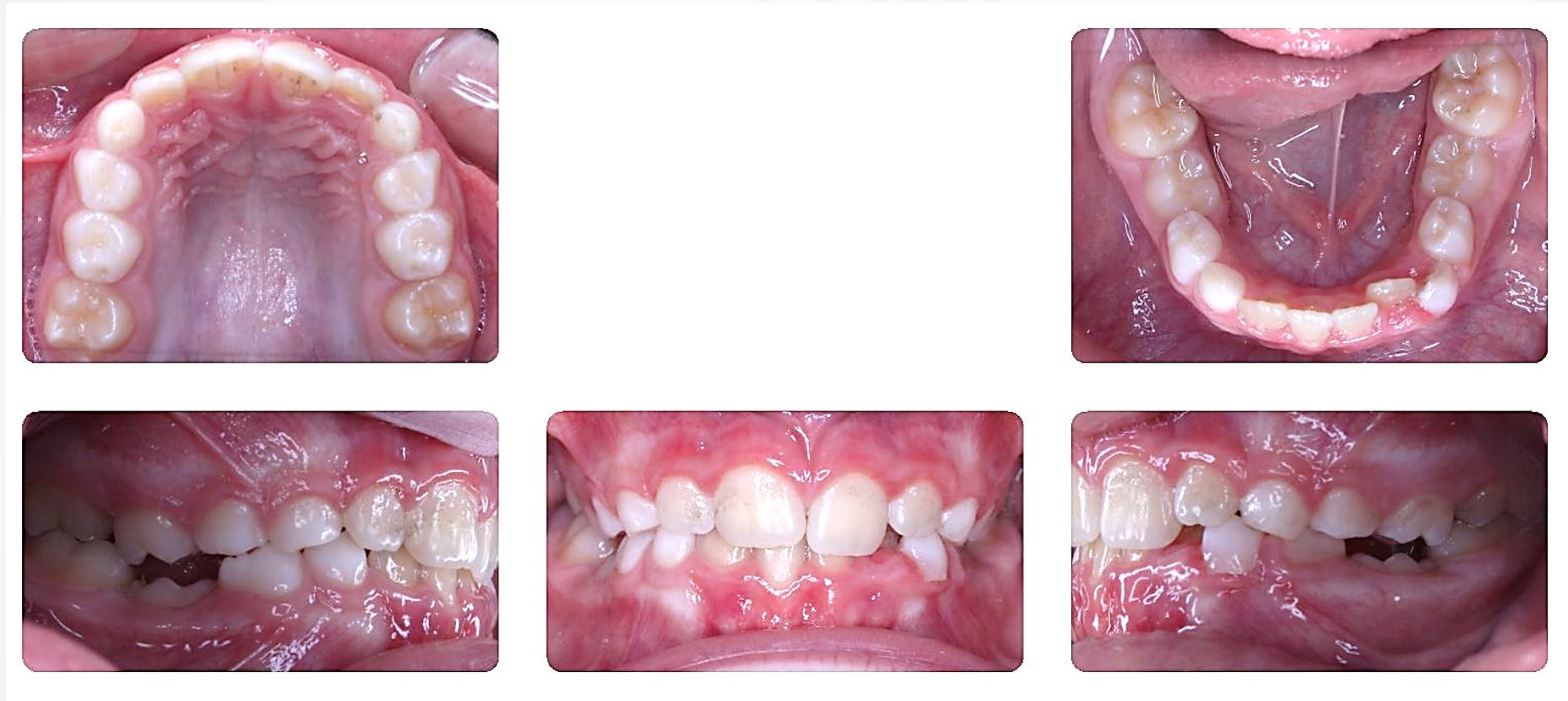Domain 2: Treatment Objectives and Planning

Prompt

List the potential complications associated with the possible ankylosis of the mandibular second deciduous molars. Please list in numbered format below.

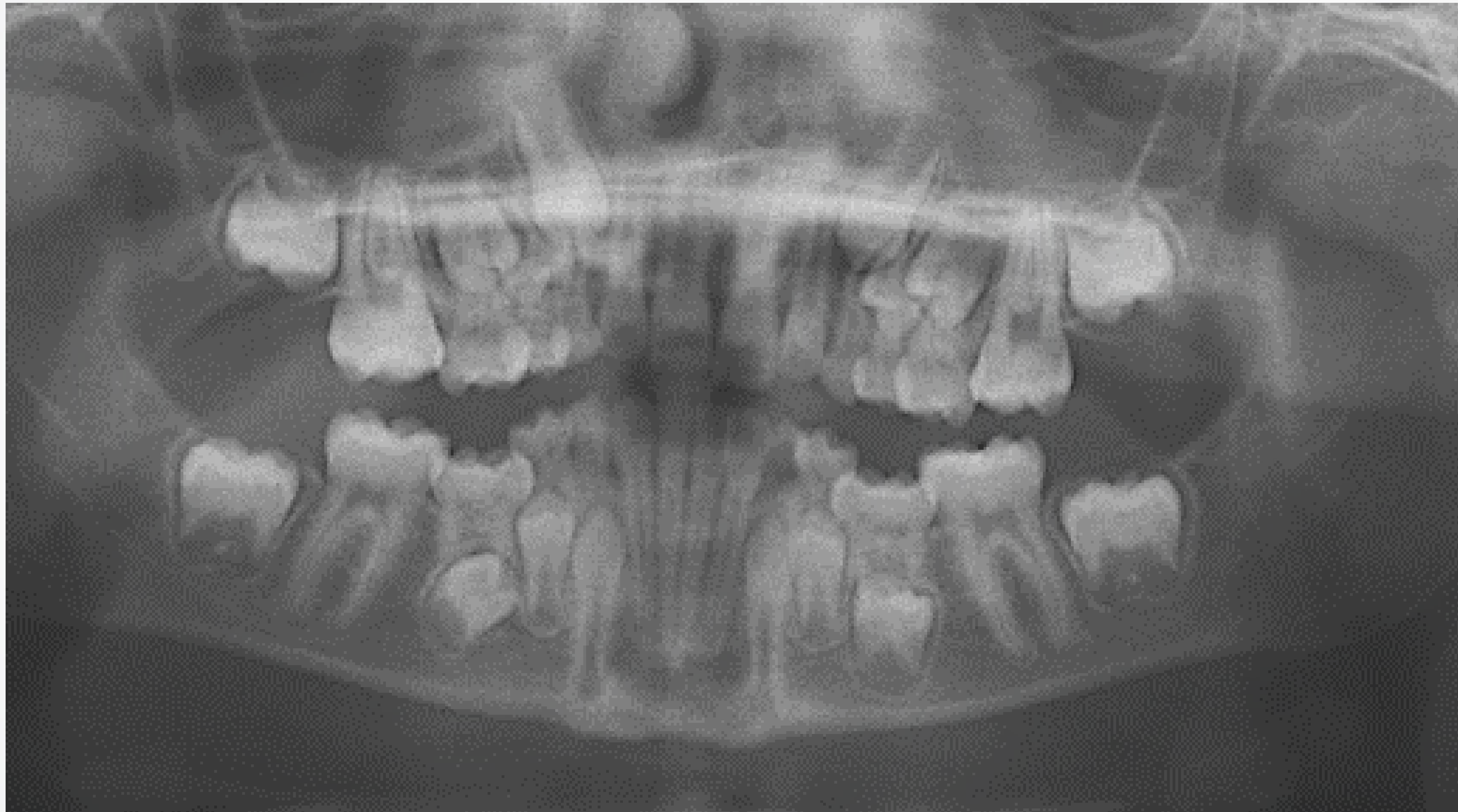
Sample Case #2

Question 2



Sample Case #2

Question 2



Sample Case #2

Question 2

Classification

Domain 2: Treatment Objectives and Planning

Prompt

List the potential complications associated with the possible ankylosis of the mandibular second deciduous molars. Please list in numbered format below.

Sample Case #2

Question 2

Fully Proficient Model Response

The examinee's response must include seven of the following:

1. Ectopic eruption of the mandibular second premolars
2. Tipping of adjacent teeth
3. Further submergence of the ankylosed mandibular second deciduous molars
4. Periodontal bony defect on the ankylosed teeth
5. Impaction of mandibular second premolars
6. Decreased arch length
7. Lateral open bite
8. Extruded antagonist maxillary tooth

Sample Case #2

Question 2

Borderline Proficient Model Response

The examinee's response must include six of the above.

Not Proficient Model Response

The examinee's response includes five or fewer of the above.

Sample Case #3

Sample Case #3

Opening Scenario:

A 12-year, 5-month-old female presents without a chief complaint. Her dentist recommended an orthodontic consultation.

Sample Case #3

Question 1

Classification

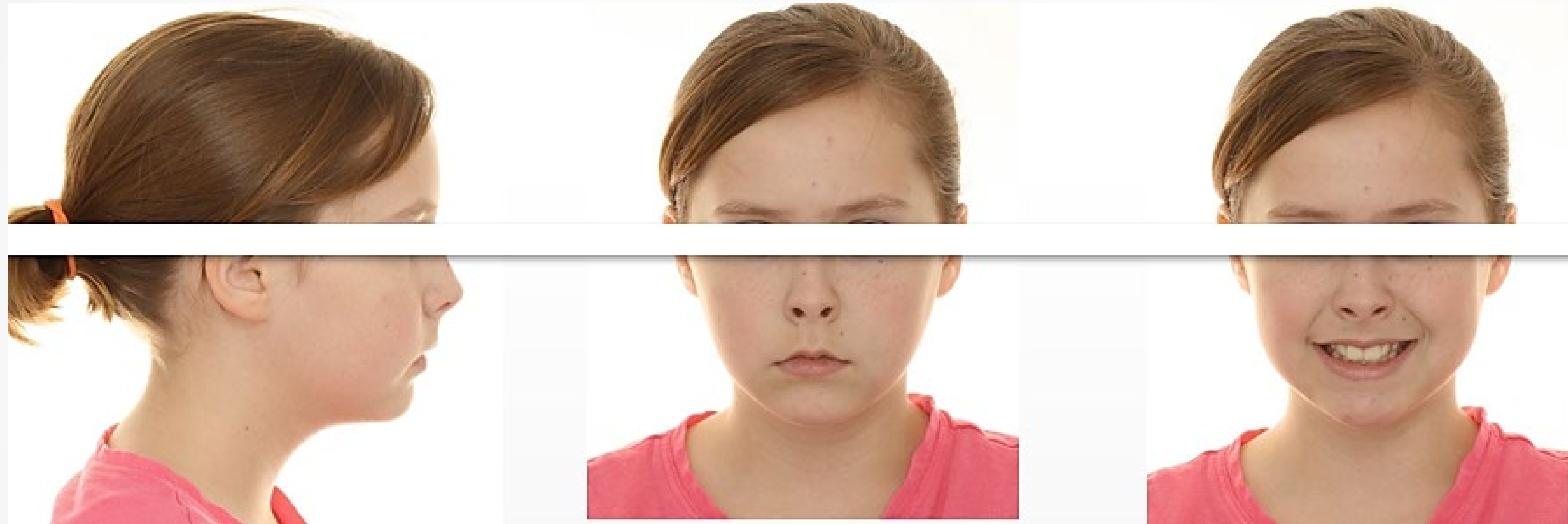Domain 1: Data Gathering and Diagnosis

Prompt

List the skeletal components of this patient's malocclusion. Please list in numbered format below.

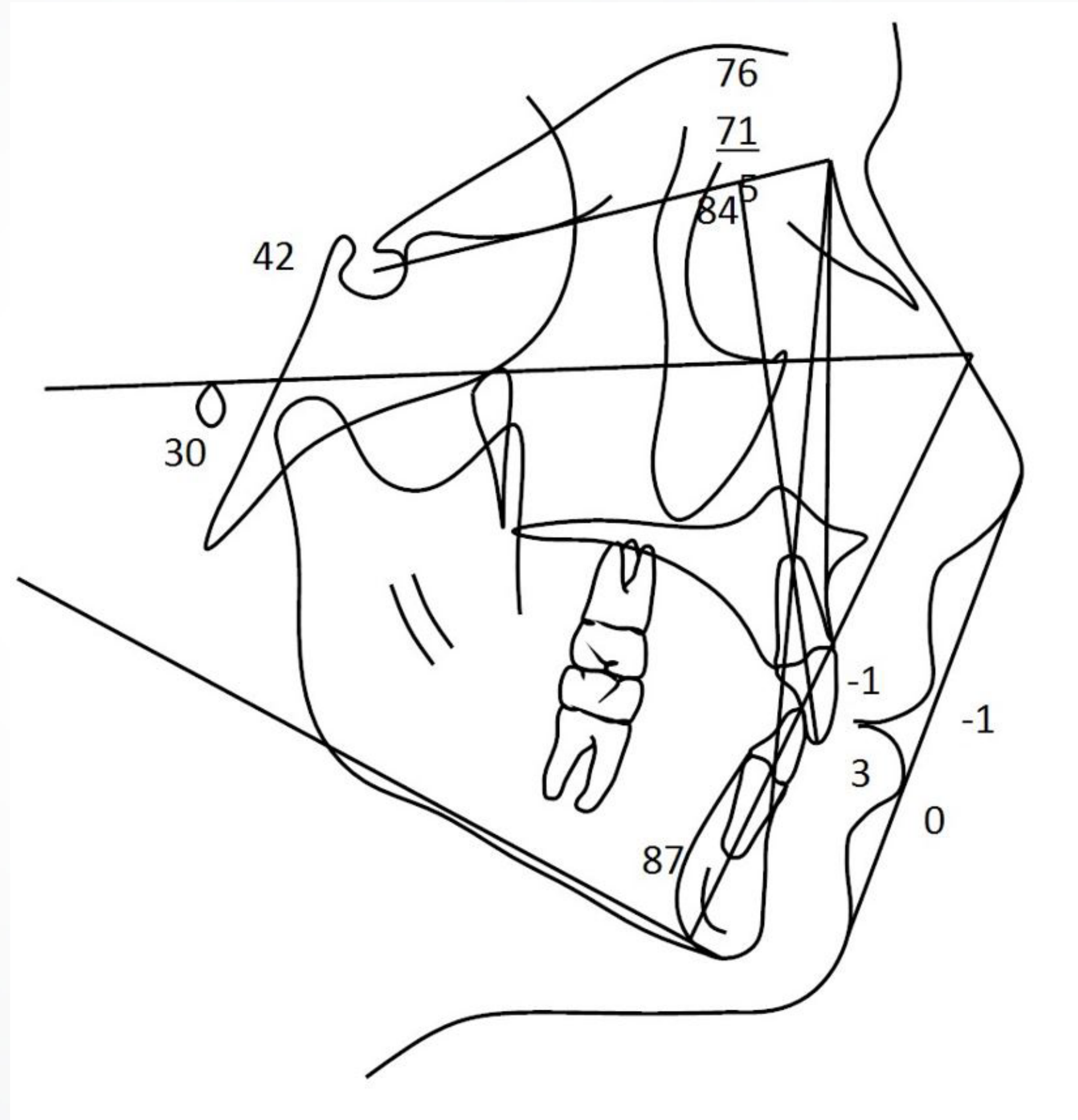
Sample Case #3

Question 1



Sample Case #3

Question 1



Sample Case #3

Question 1

Classification

Domain 1: Data Gathering and Diagnosis

Prompt

List the skeletal components of this patient's malocclusion. Please list in numbered format below.

Sample Case #3

Question 1

Fully Proficient Model Response

The examinee's response must include all of the following:

1. Steep cranial base
2. Skeletal Class II
3. Normal maxilla in A-P
4. Retrusive/retrognathic mandible
5. Normodivergent (hyperdivergent tendency is also acceptable)

Sample Case #3

Question 1

Borderline Proficient Model Response

The examinee's response must include four of the above.

Not Proficient Model Response

The examinee's response includes three or fewer of the above.

Sample Case #3

Question 2

Classification

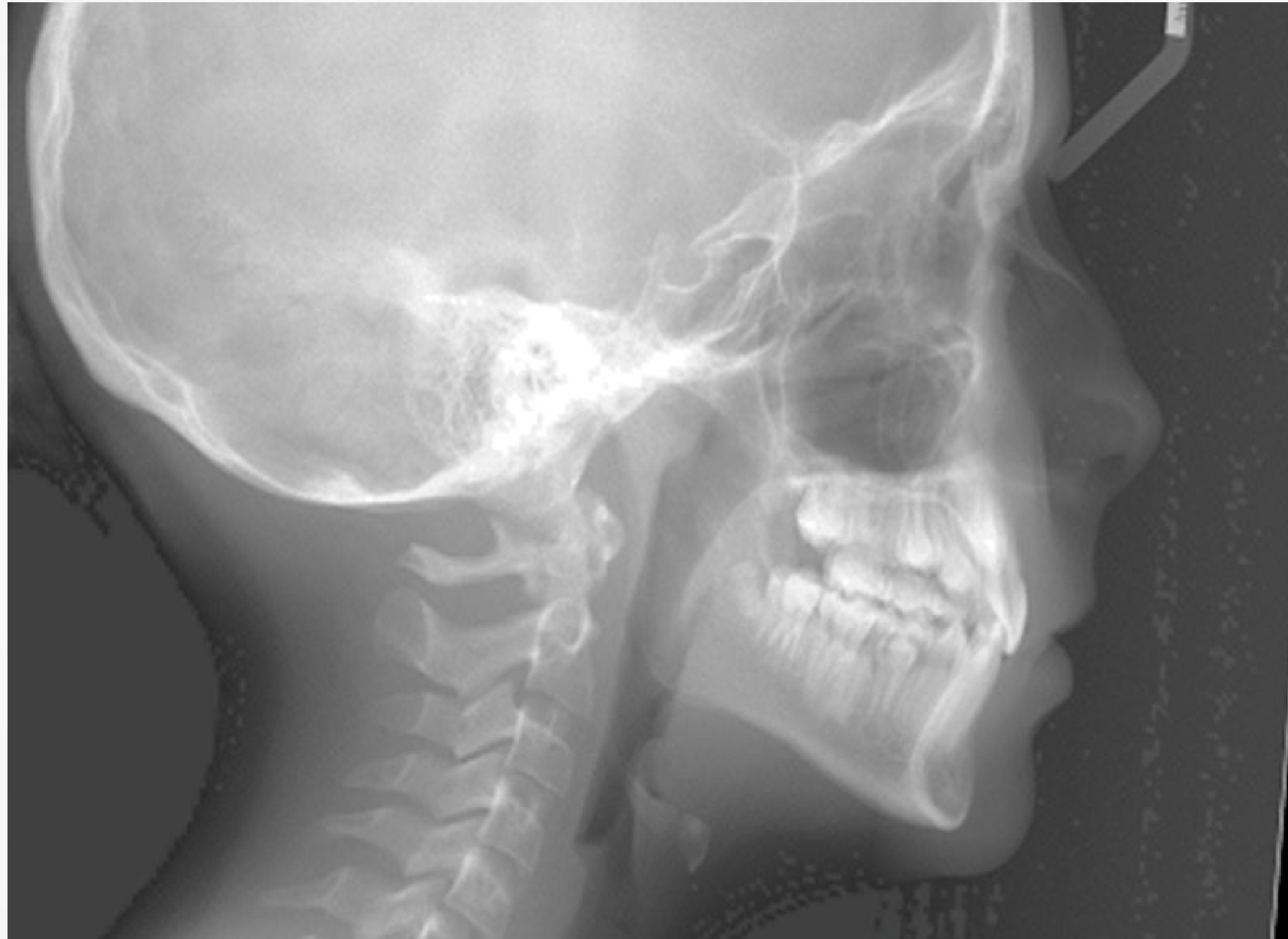Domain 2: Treatment Objectives and Planning

Prompt

Describe the patient's skeletal stage and growth potential. Please list in numbered format below.

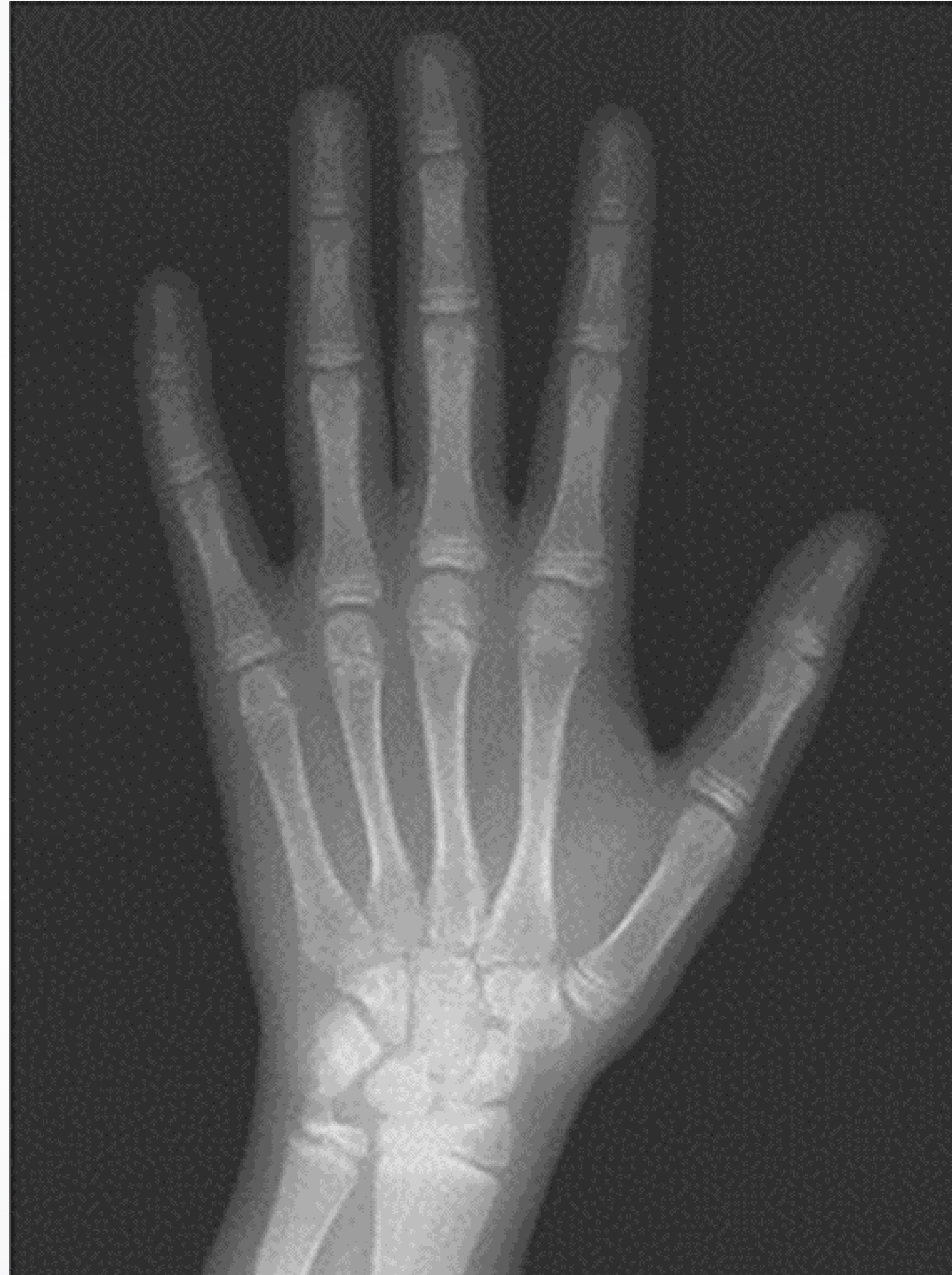Sample Case #3

Question 2



Sample Case #3

Question 2



Sample Case #3

Question 2

Classification

Domain 2: Treatment Objectives and Planning

Prompt

Describe the patient's skeletal stage and growth potential. Please list in numbered format below.

Sample Case #3

Question 2

Fully Proficient Model Response

The examinee's response must include all of the following:

1. Cervical Vertebral Maturation Stage (CVMS) is 2 (accept between 2 and 3)
2. Skeletal Maturation Indicator (SMI) is 3 to 4
3. Patient is approaching peak mandibular growth, expected in the next 1 to 1.5 years.

Sample Case #3

Question 2

Borderline Proficient Model Response

The examinee's response must include two of the above.

Not Proficient Model Response

The examinee's response includes one or none of the above.

Sample Case #3

Question 3

Classification

Domain 4: Critical Analysis and Outcomes Assessment

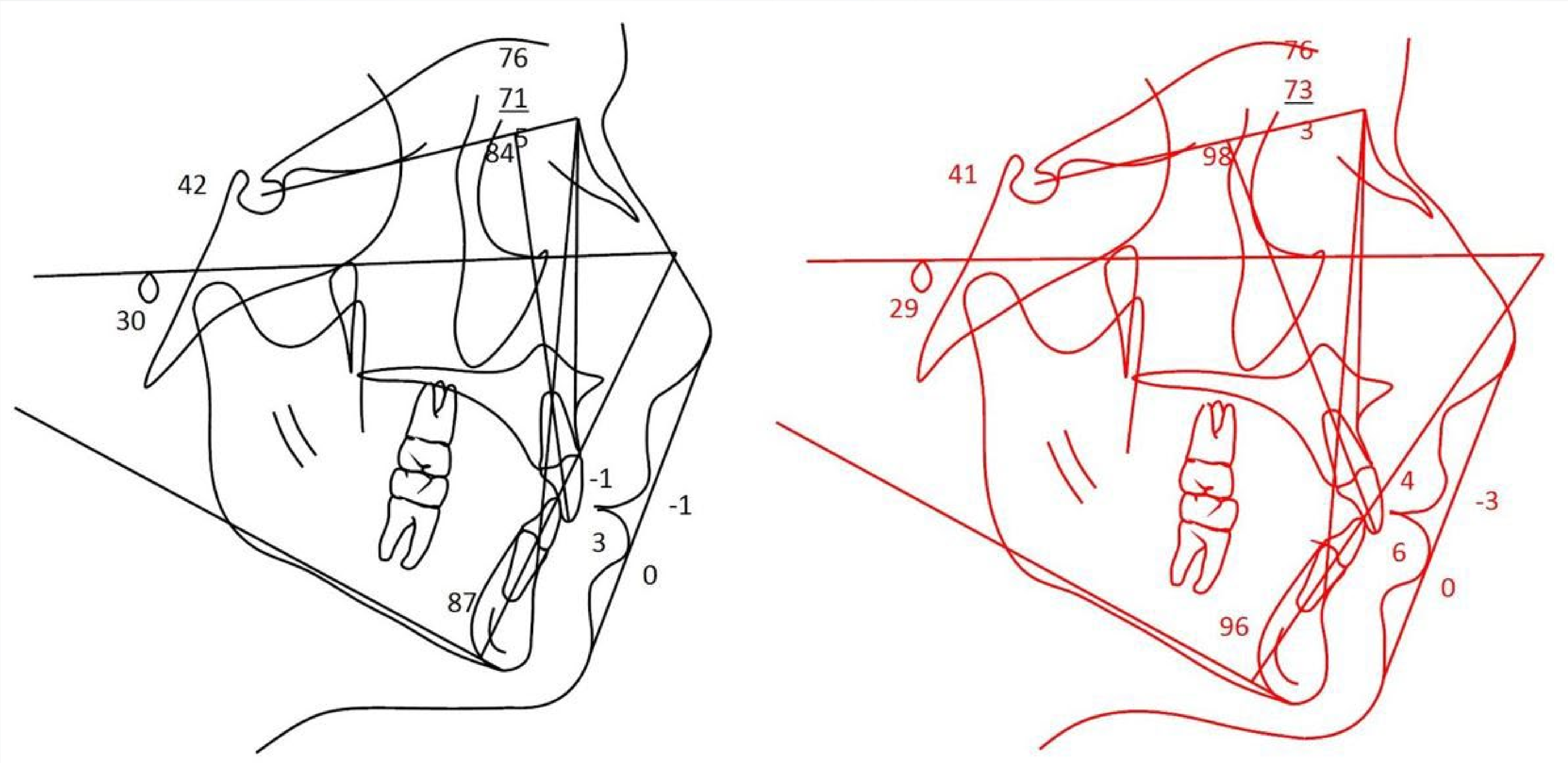
Prompt

This patient was treated with comprehensive, nonextraction orthodontic treatment. The time between pretreatment and posttreatment records was 34 months.

What dental changes occurred as the result of treatment? Please list in numbered format below.

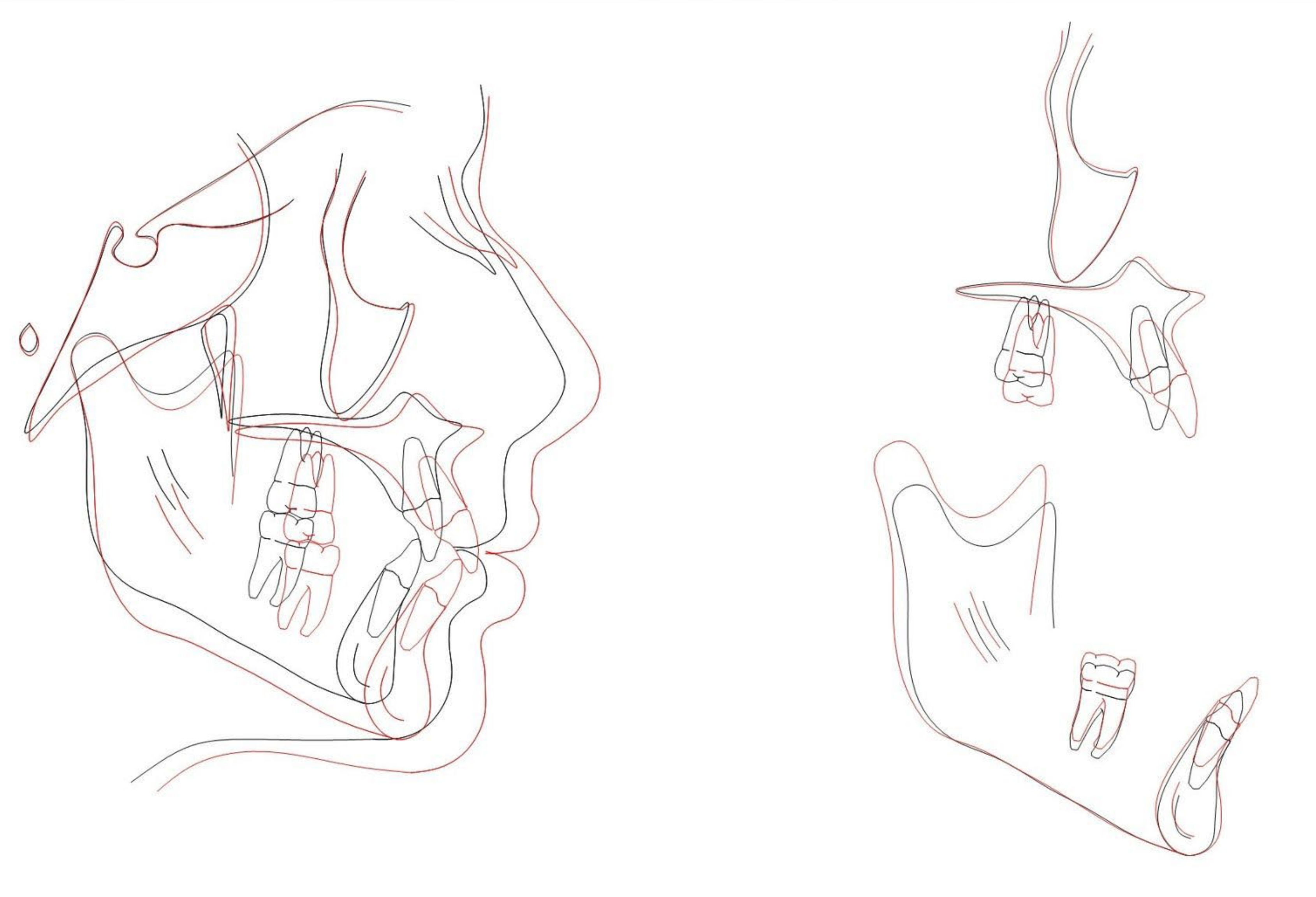
Sample Case #3

Question 3



Sample Case #3

Question 3



Sample Case #3

Question 3

Classification

Domain 4: Critical Analysis and Outcomes Assessment

Prompt

This patient was treated with comprehensive, nonextraction orthodontic treatment. The time between pretreatment and posttreatment records was 34 months.

What dental changes occurred as the result of treatment? Please list in numbered format below.

Sample Case #3

Question 3

Fully Proficient Model Response

The examinee's response must include all of the following:

1. Maxillary molars extruded
2. Maxillary incisors proclined
3. Mandibular molars held in A-P
4. Mandibular incisors proclined
5. Mandibular molars were held vertically

Sample Case #3

Question 3

Borderline Proficient Model Response

The examinee's response must include four of the above.

Not Proficient Model Response

The examinee's response includes three or fewer of the above.

Sample Case #4

Sample Case #4

Opening Scenario:

A 14-year, 9-month-old female presents with a chief complaint that “I don’t like my bite.”

Sample Case #4

Question 1

Classification

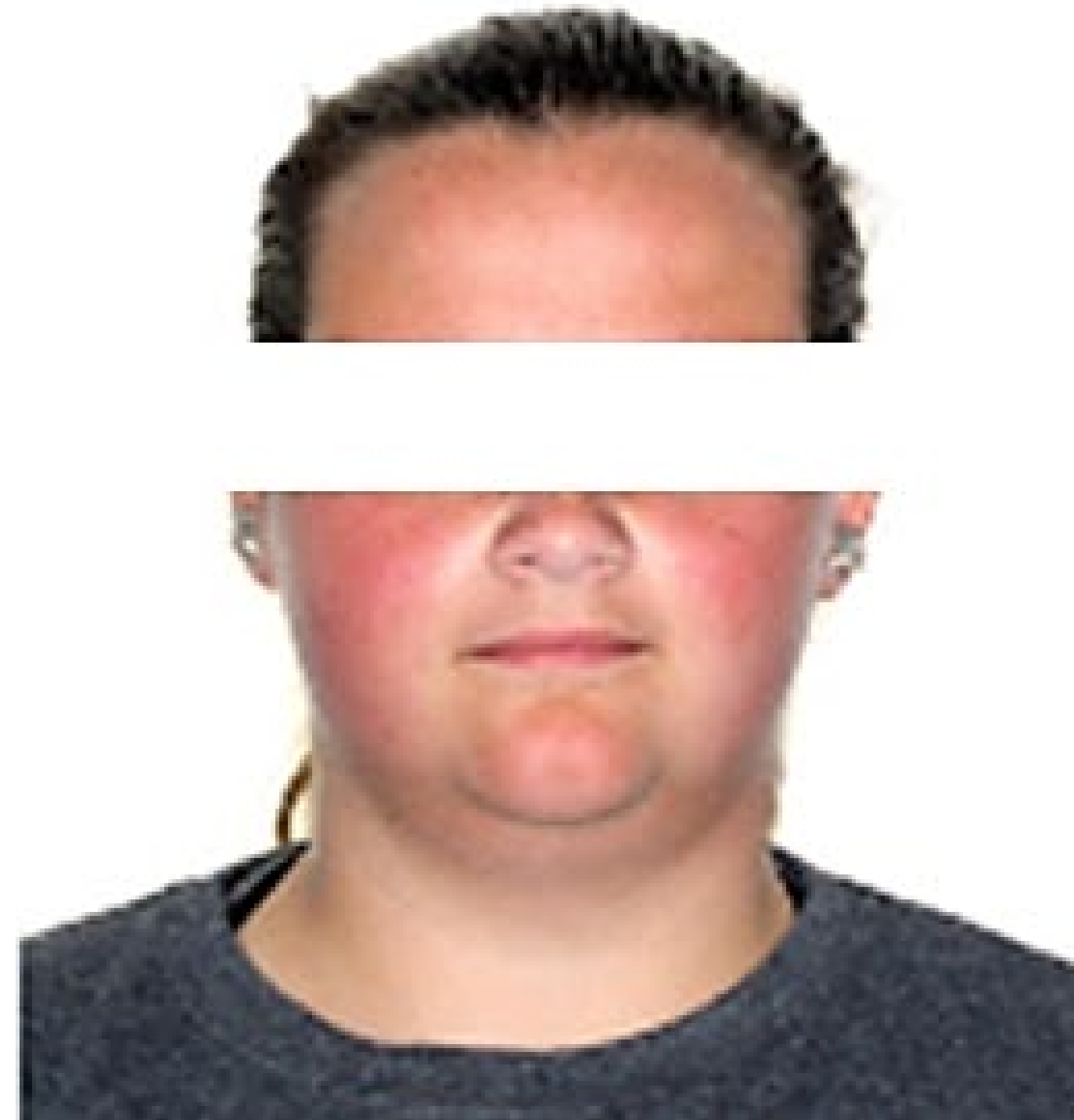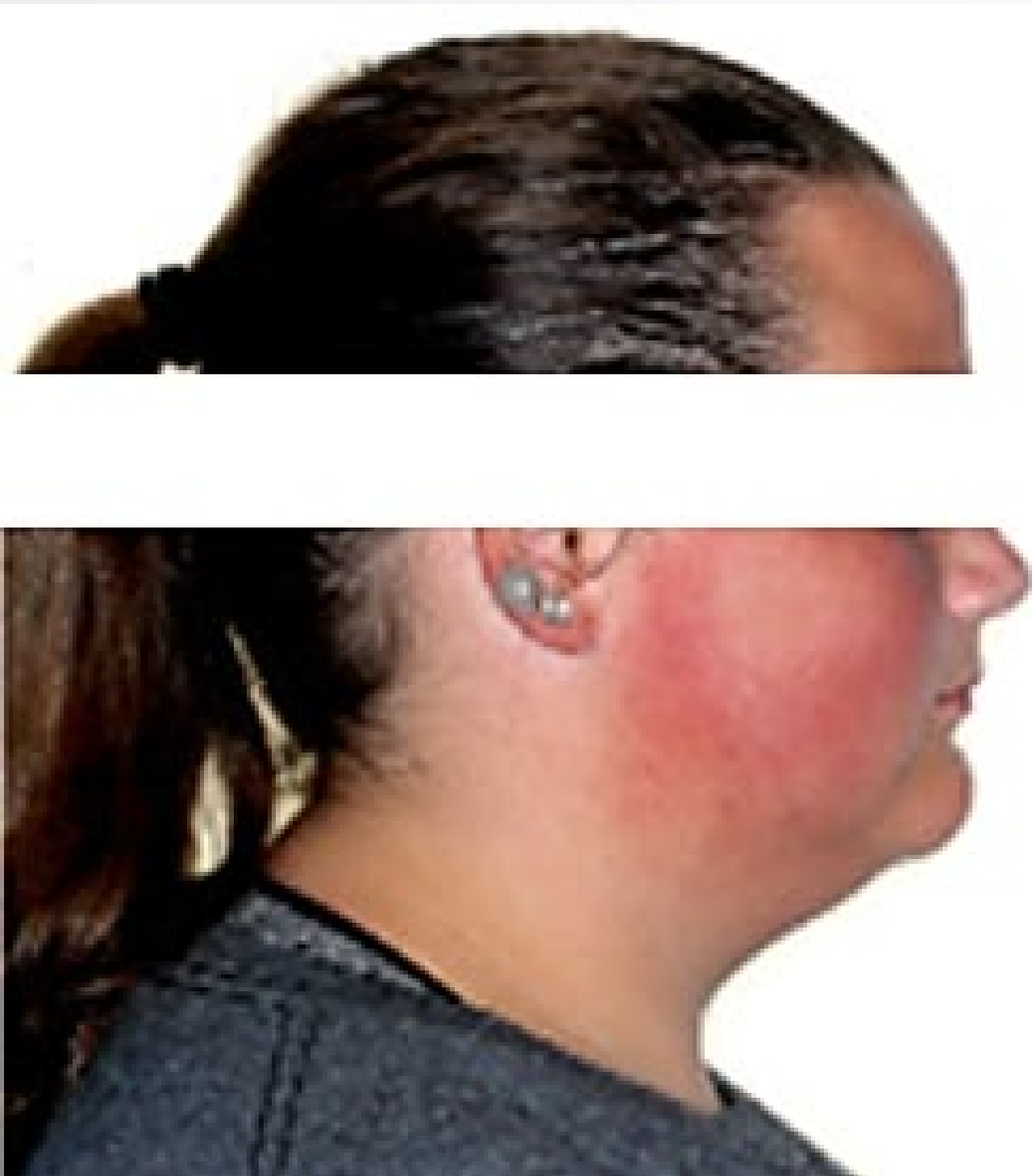Domain 1: Data Gathering and Diagnosis

Prompt

Describe the facial characteristics of this patient. Please list in numbered format below.

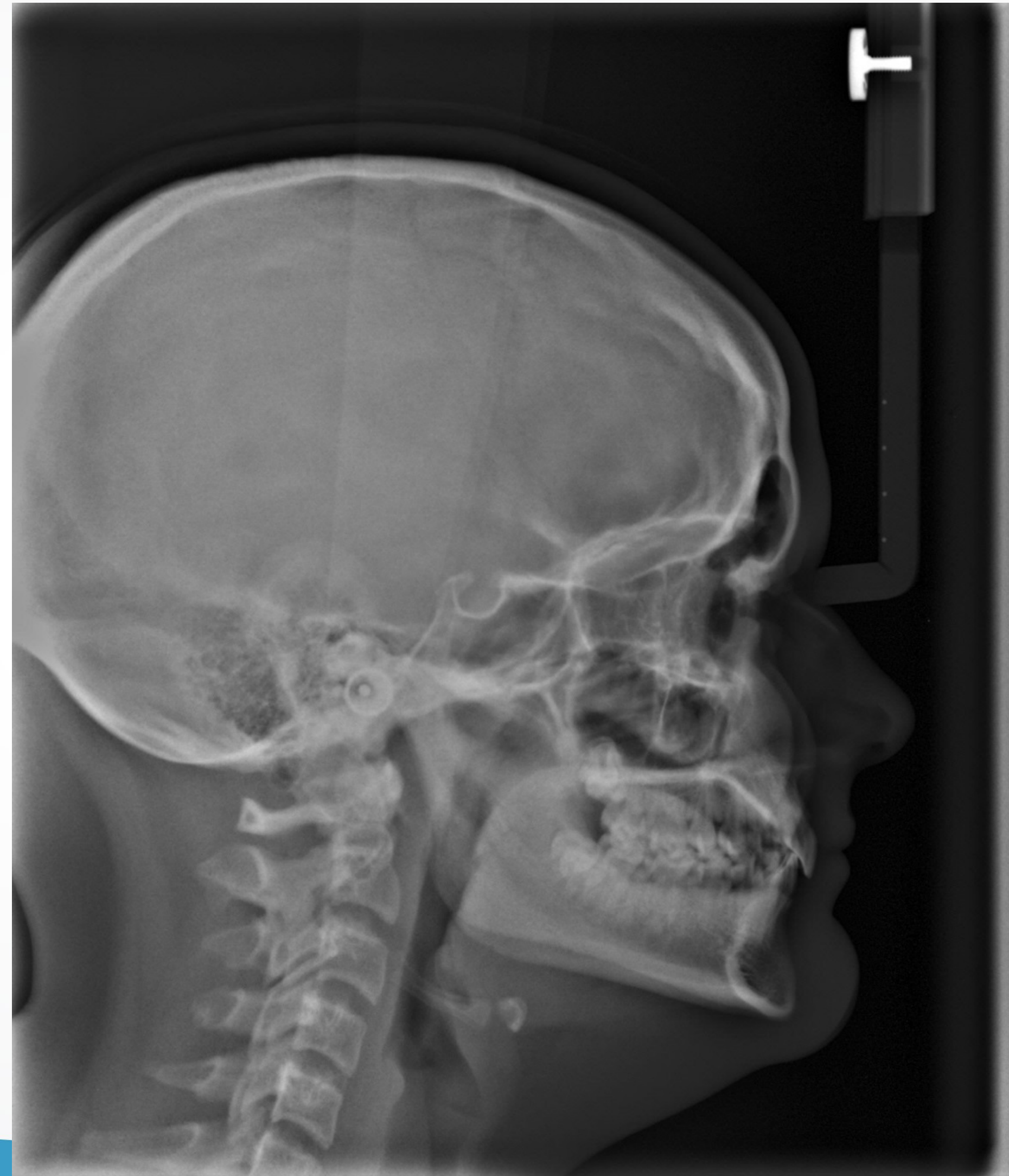Sample Case #4

Question 1



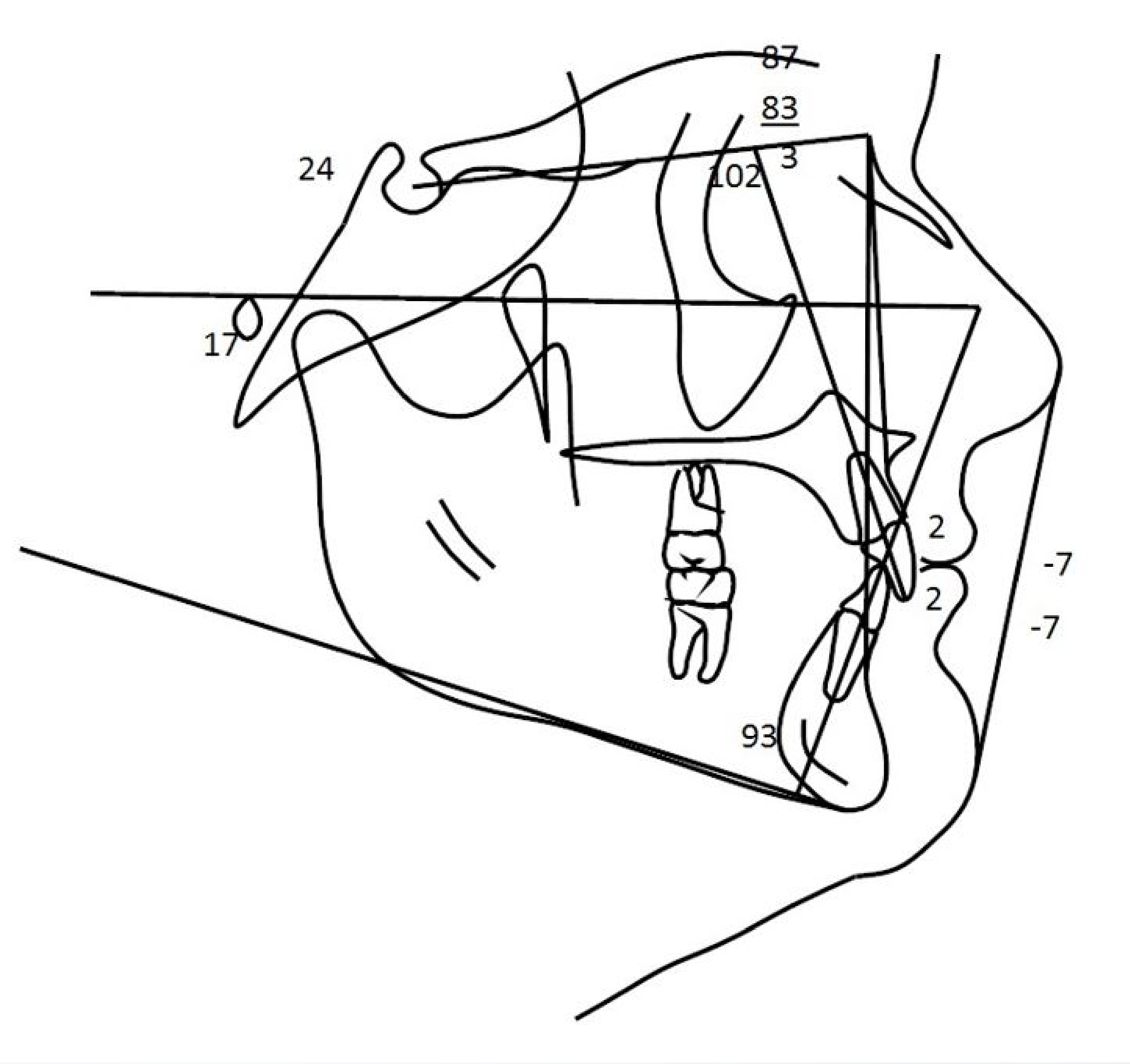
Sample Case #4

Question 1



Sample Case #4

Question 1



Sample Case #4

Question 1

Classification

Domain 1: Data Gathering and Diagnosis

Prompt

Describe the facial characteristics of this patient. Please list in numbered format below.

Sample Case #4

Question 1

Fully Proficient Model Response

The examinee's response must include five or more of the following:

1. Straight profile
2. Prominent soft tissue pogonion
3. Deep mentolabial sulcus
4. Obtuse nasiolabial angle
5. Obtuse chin-throat angle/ Poor chin-neck contour
6. Deficient vermilion display
7. Thin lips

Sample Case #4

Question 1

Borderline Proficient Model Response

The examinee's response must include four of the above.

Not Proficient Model Response

The examinee's response includes three or fewer of the above.

Sample Case #5

Sample Case #5

Opening Scenario:

A 13-year, 8-month-old female patient presents with the chief complaint that “My teeth are not straight.”

Sample Case #5

Question 1

Classification

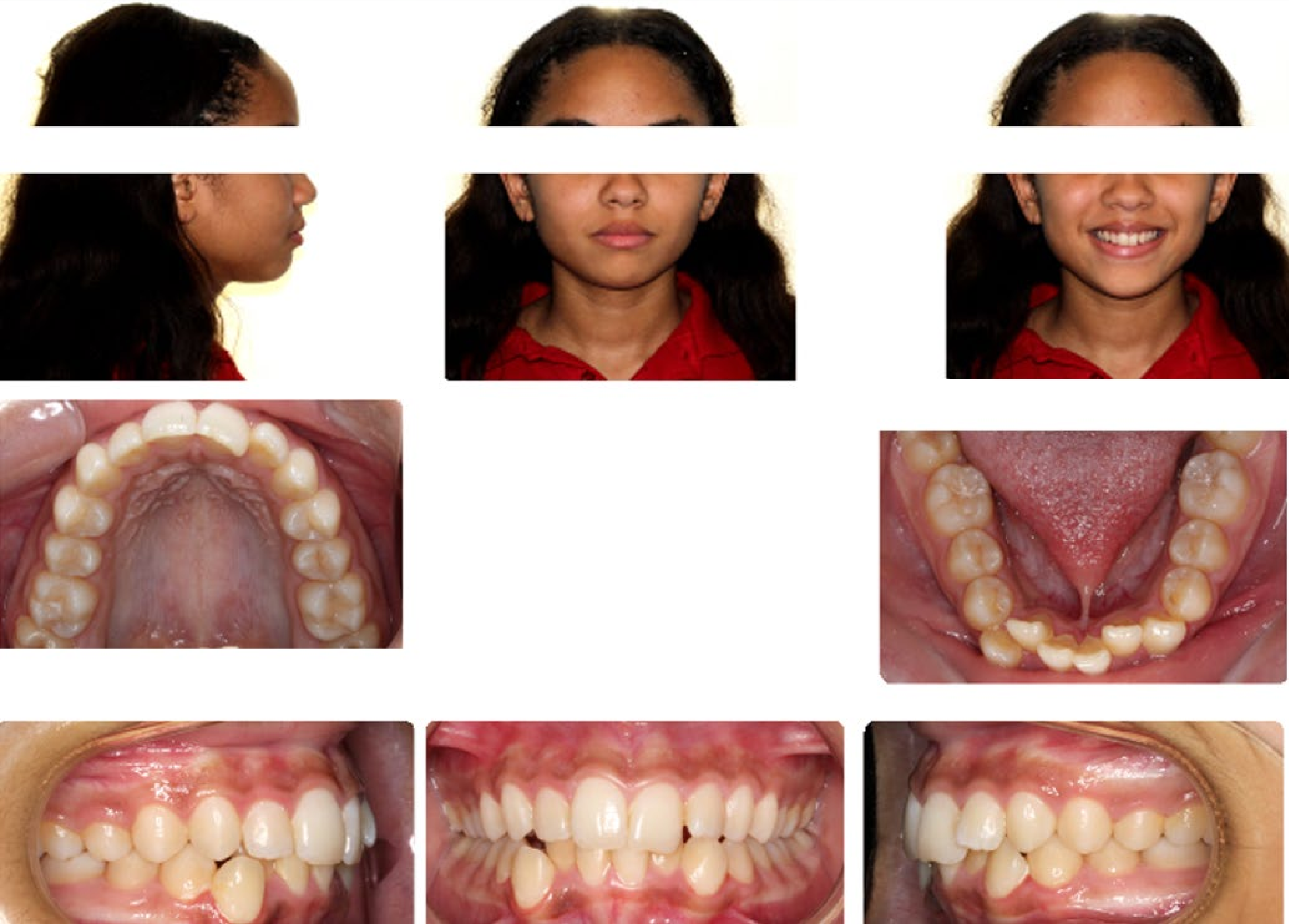Domain 2: Treatment Objectives and Planning

Prompt

Identify treatment objectives for the maxillary and mandibular incisors.
Please list in numbered format below.

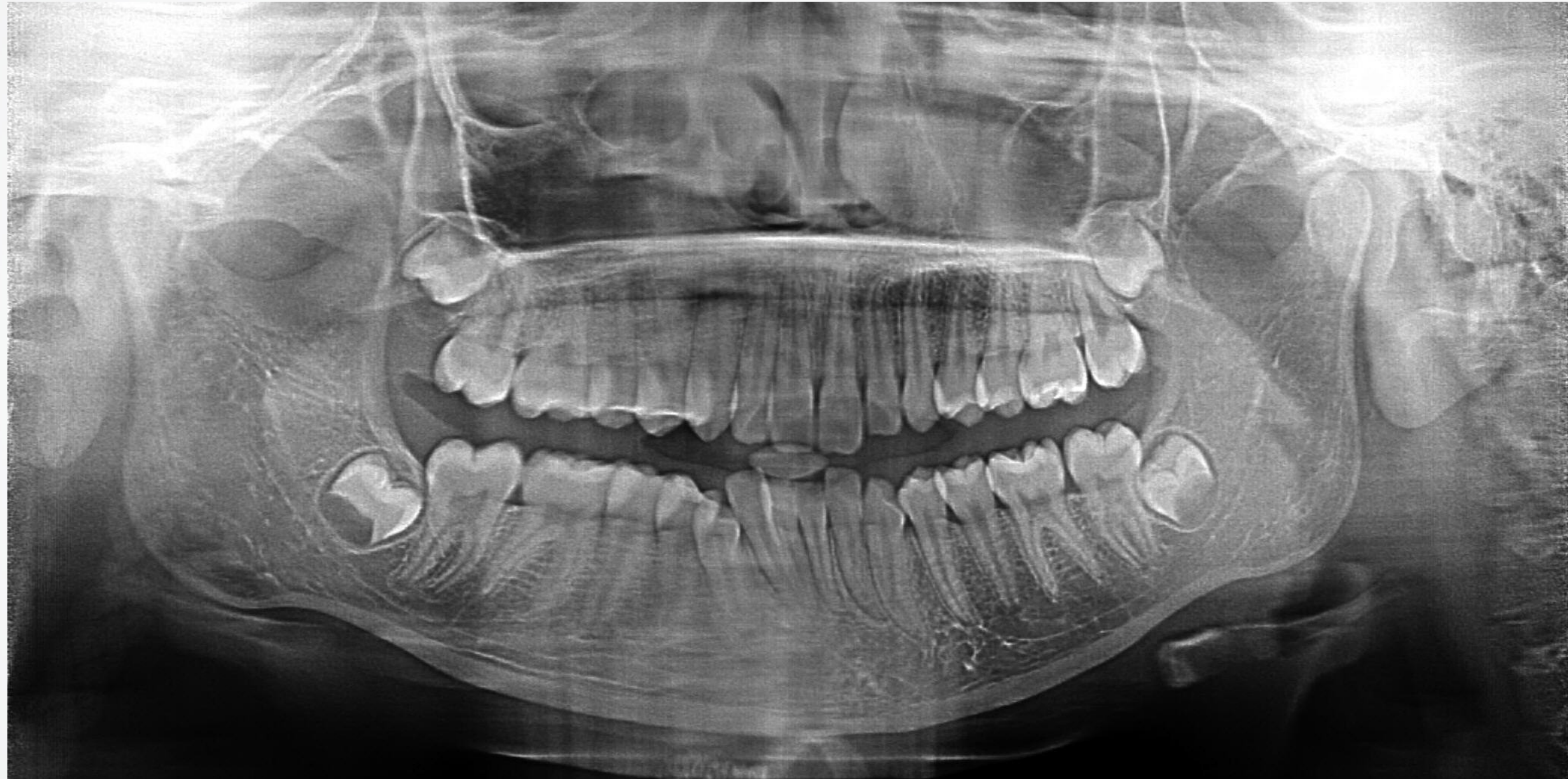Sample Case #5

Question 1



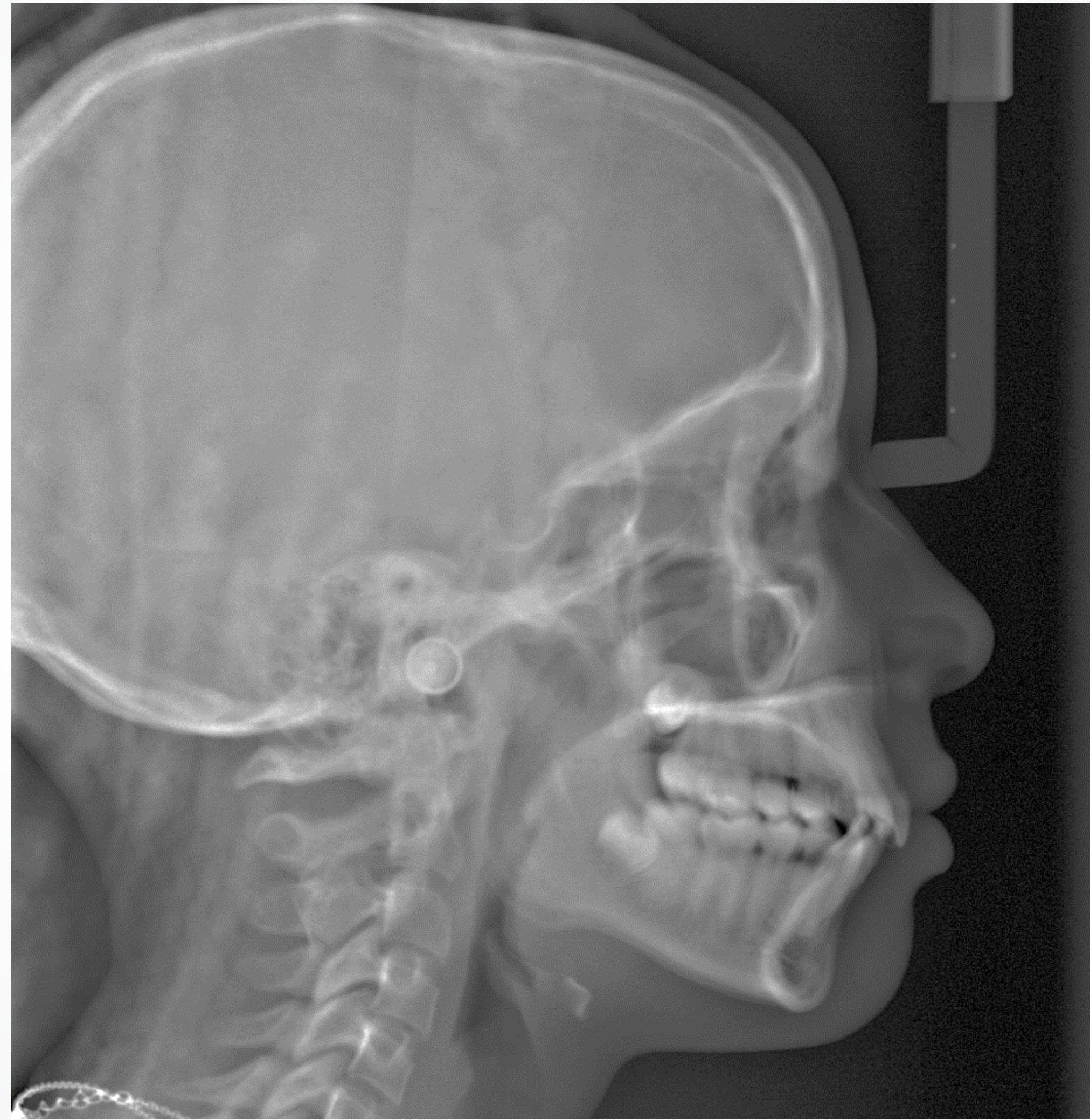
Sample Case #5

Question 1



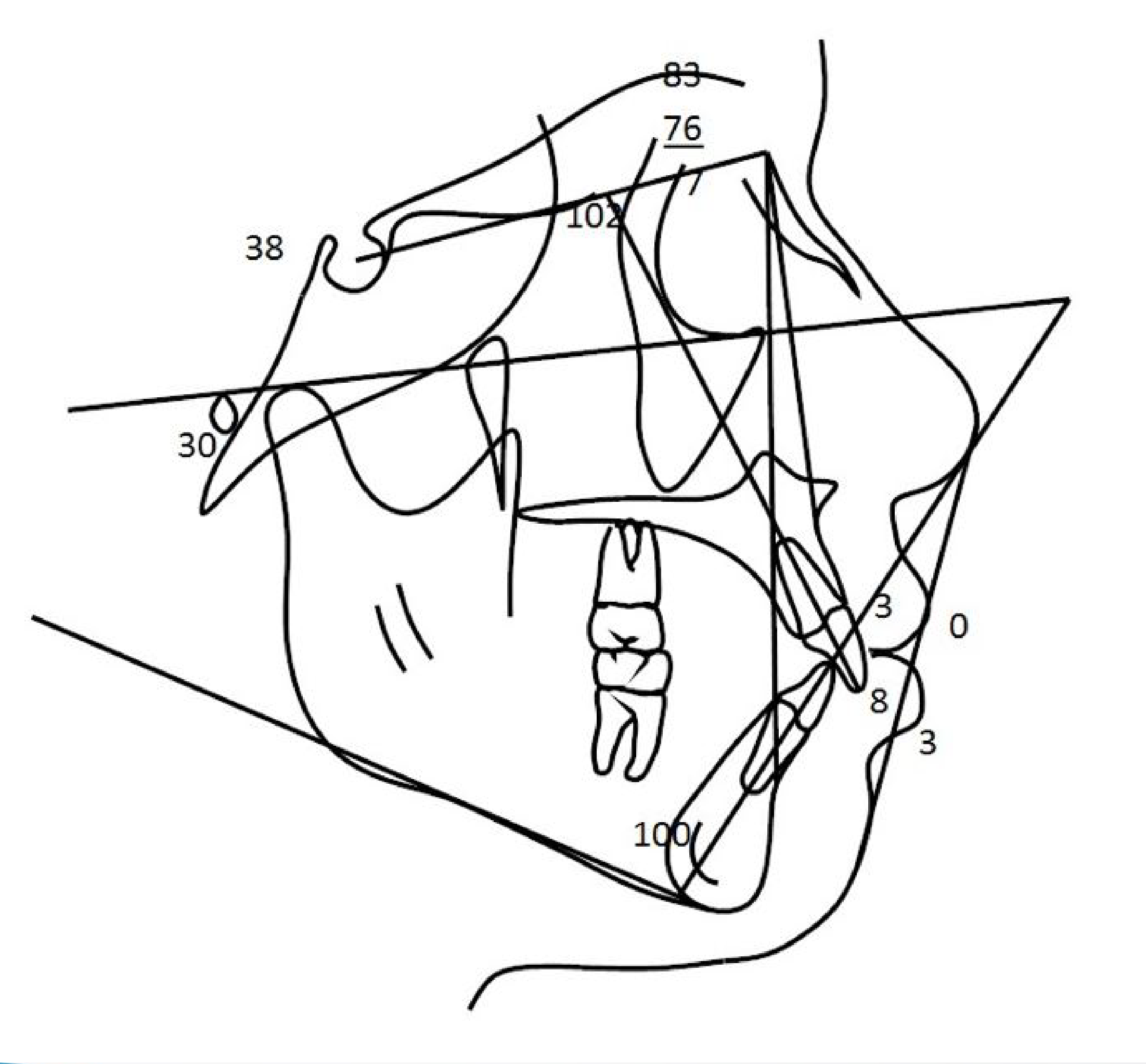
Sample Case #5

Question 1



Sample Case #5

Question 1



Sample Case #5

Question 1

Classification

Domain 2: Treatment Objectives and Planning

Prompt

Identify treatment objectives for the maxillary and mandibular incisors.
Please list in numbered format below.

Sample Case #5

Question 1

Fully Proficient Model Response

The examinee's response must include five or more of the following:

1. Retract the maxillary incisors
2. Maintain maxillary incisor inclination (maintain torque)
3. Maintain vertical position of maxillary incisors (accept slight intrusion)
4. Retrocline mandibular incisors
5. Intrude mandibular incisors (level the curve of Spee)
6. Correct the mandibular dental midline

Sample Case #5

Question 1

Borderline Proficient Model Response

The examinee's response must include four of the above.

Not Proficient Model Response

The examinee's response includes three or fewer of the above.