ILLUSTRATION ONLY. PHOTO MONTAGE IS NOT REQUIRED.

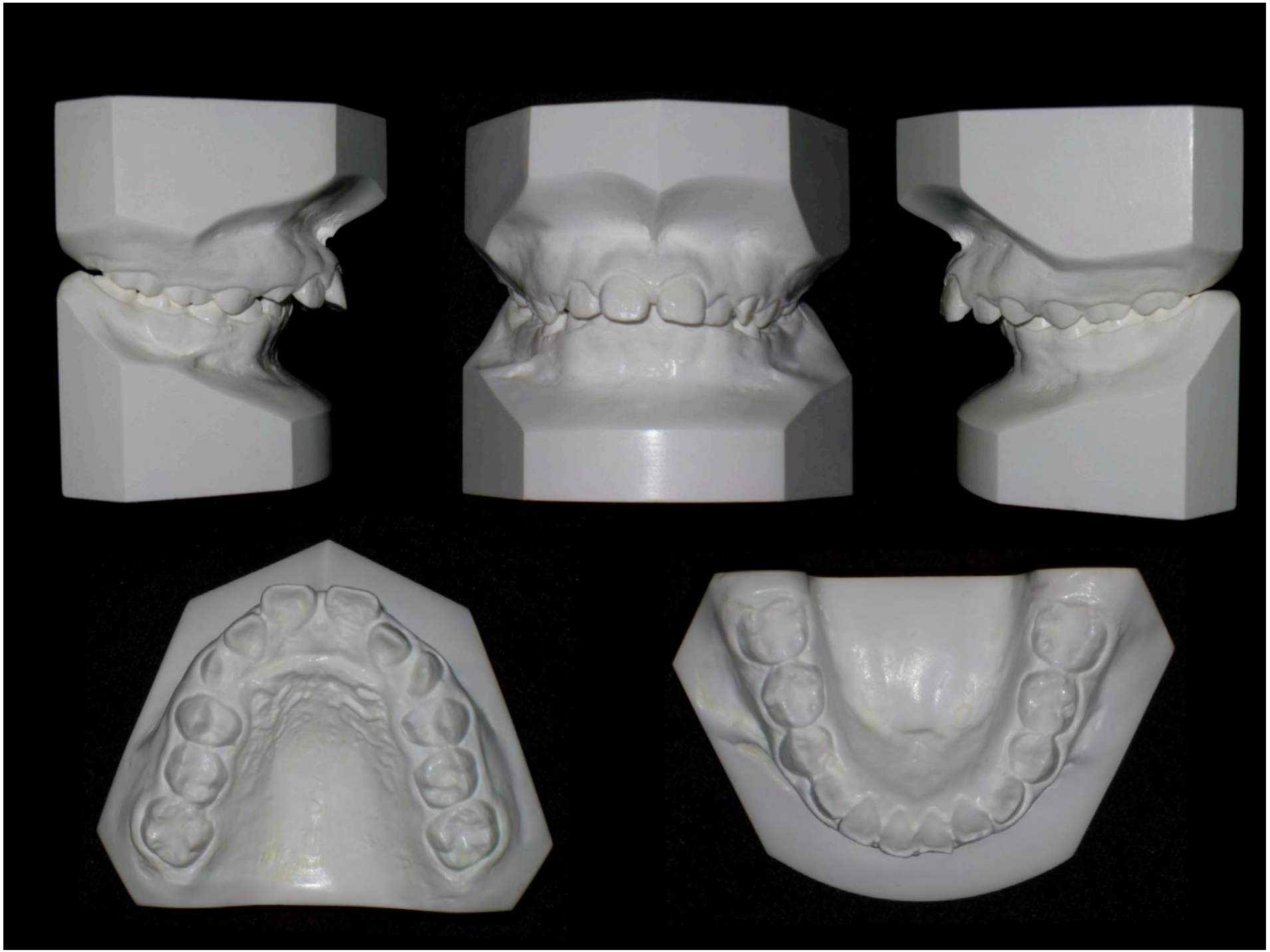

ILLUSTRATION ONLY. PHOTO MONTAGE IS NOT REQUIRED.

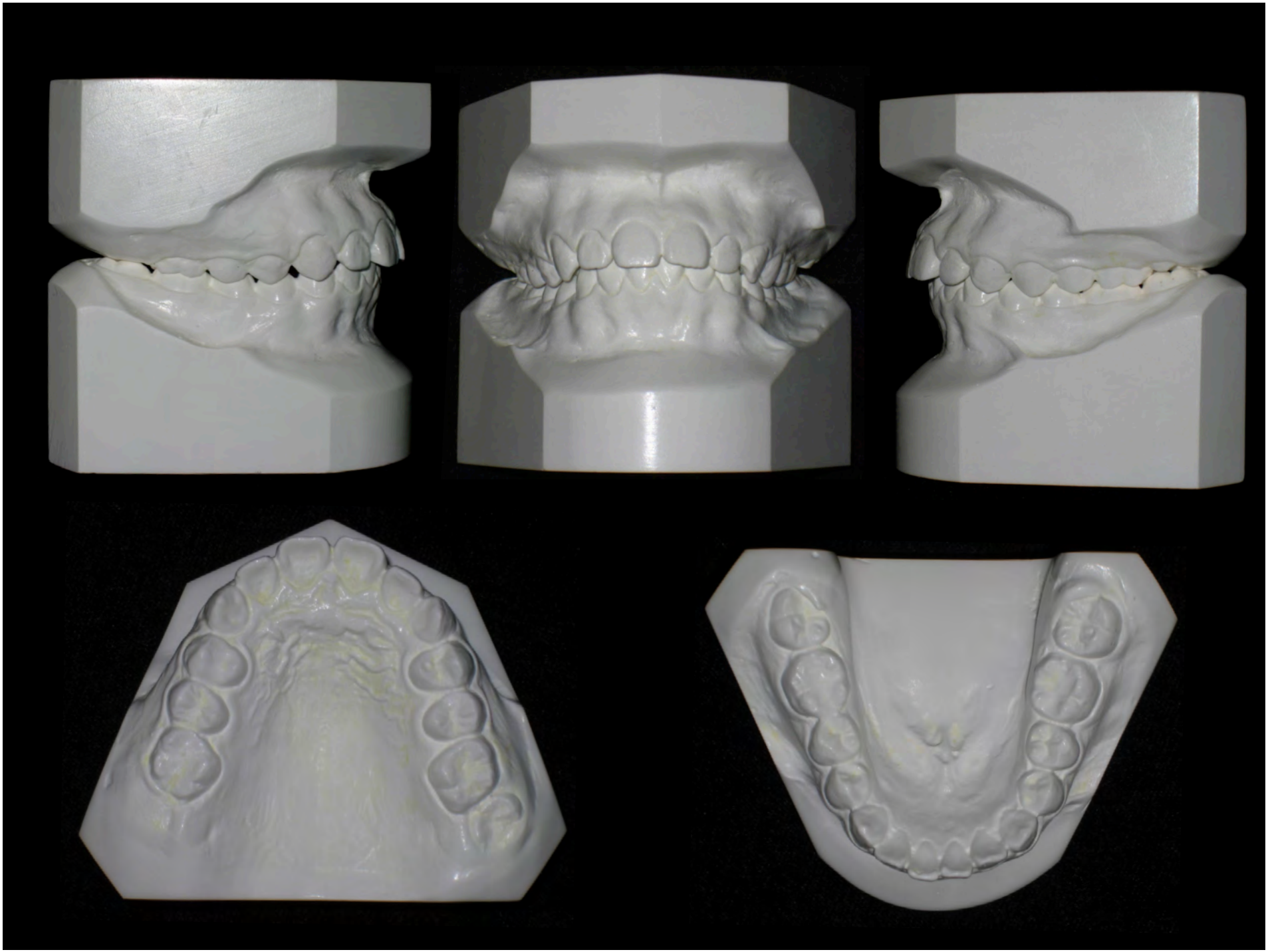

ILLUSTRATION ONLY. PHOTO MONTAGE IS NOT REQUIRED.

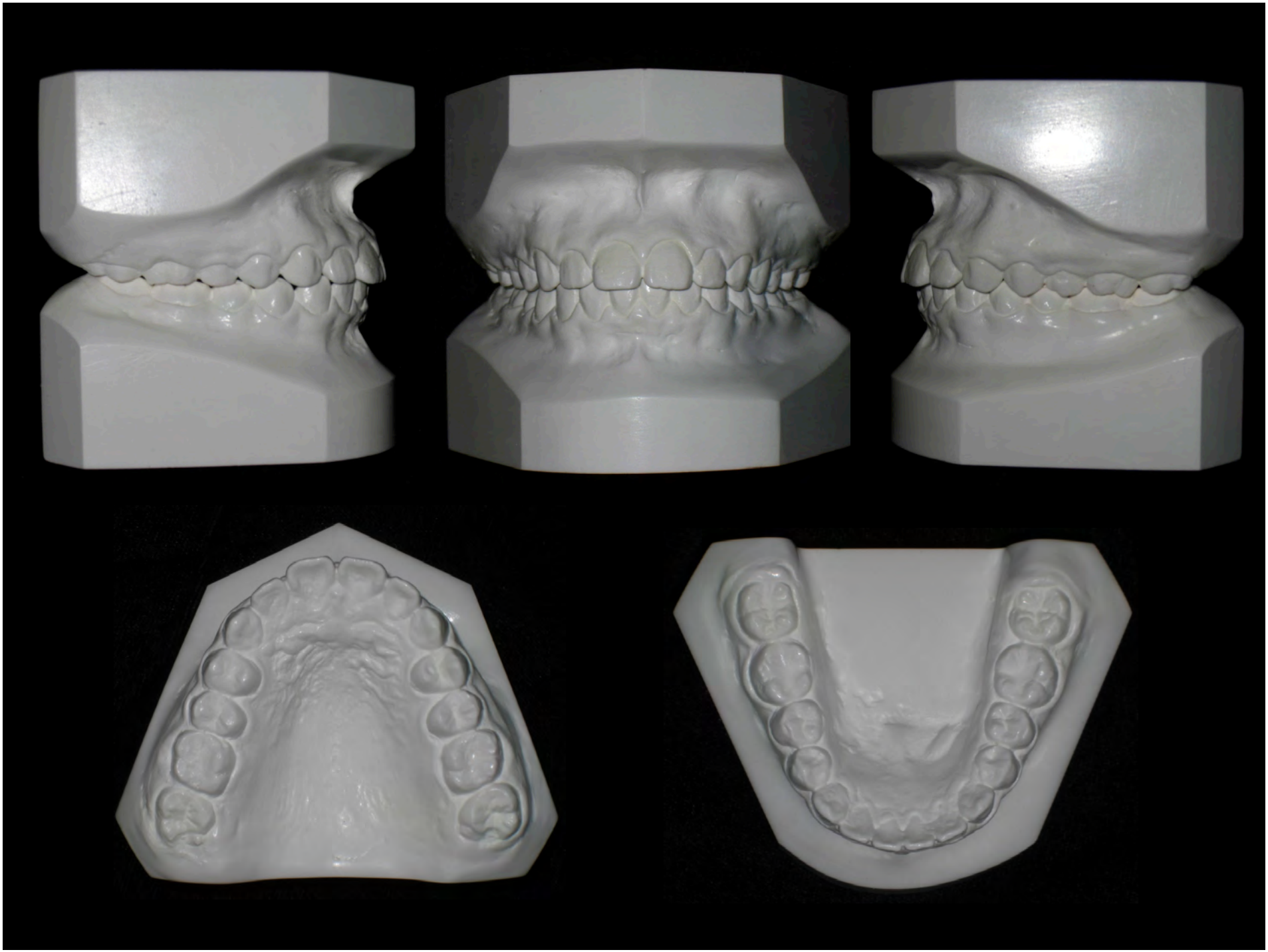

The American Board of Orthodontics

Case Report
Title Page

Case #4

DI – 24

Class II Case

Patient's Name: Anna Marie

ABO ID# 03232

ID# 03232 #4

4-28-05 9-1

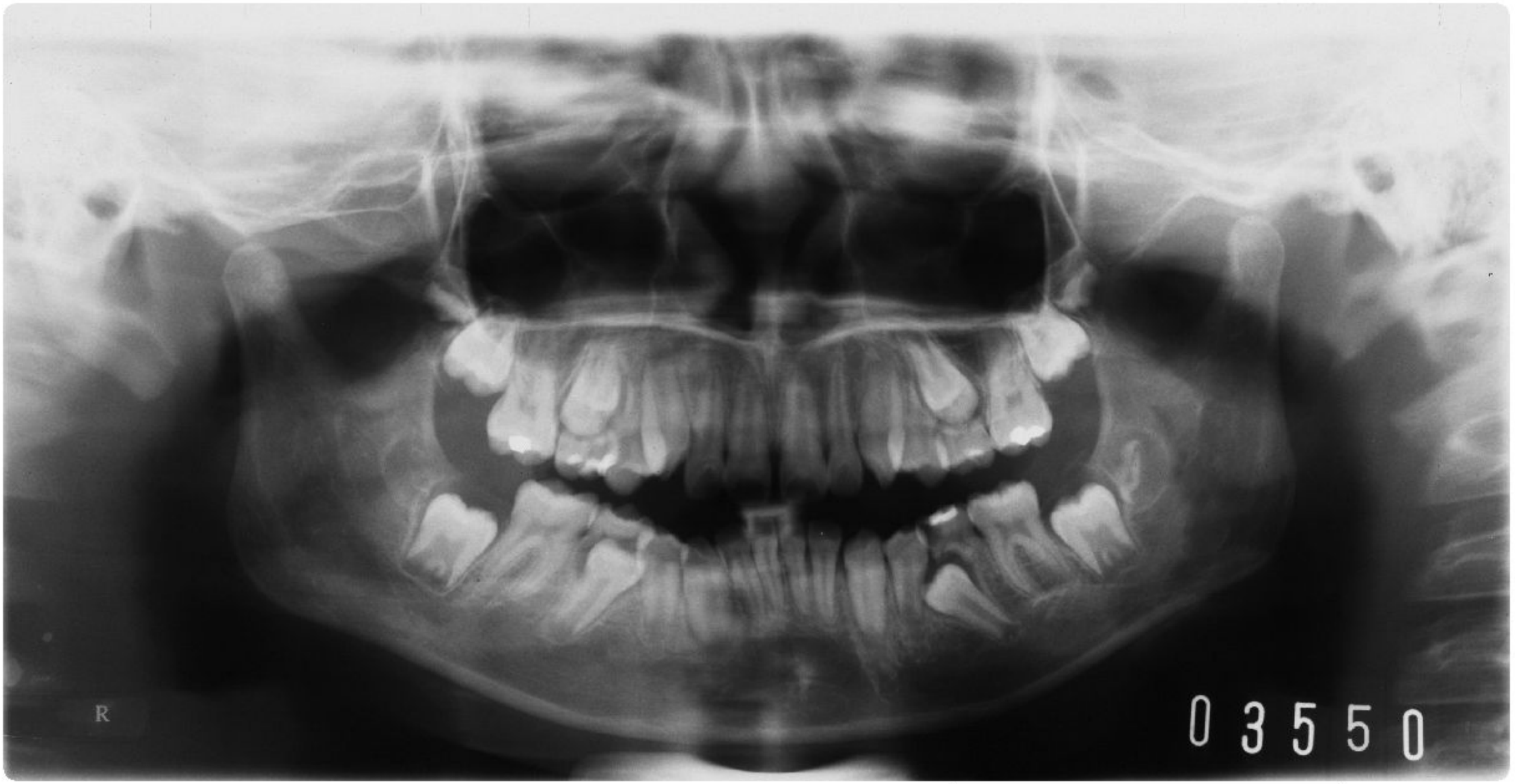

ID# 03232 #4

4-28-05 9-1

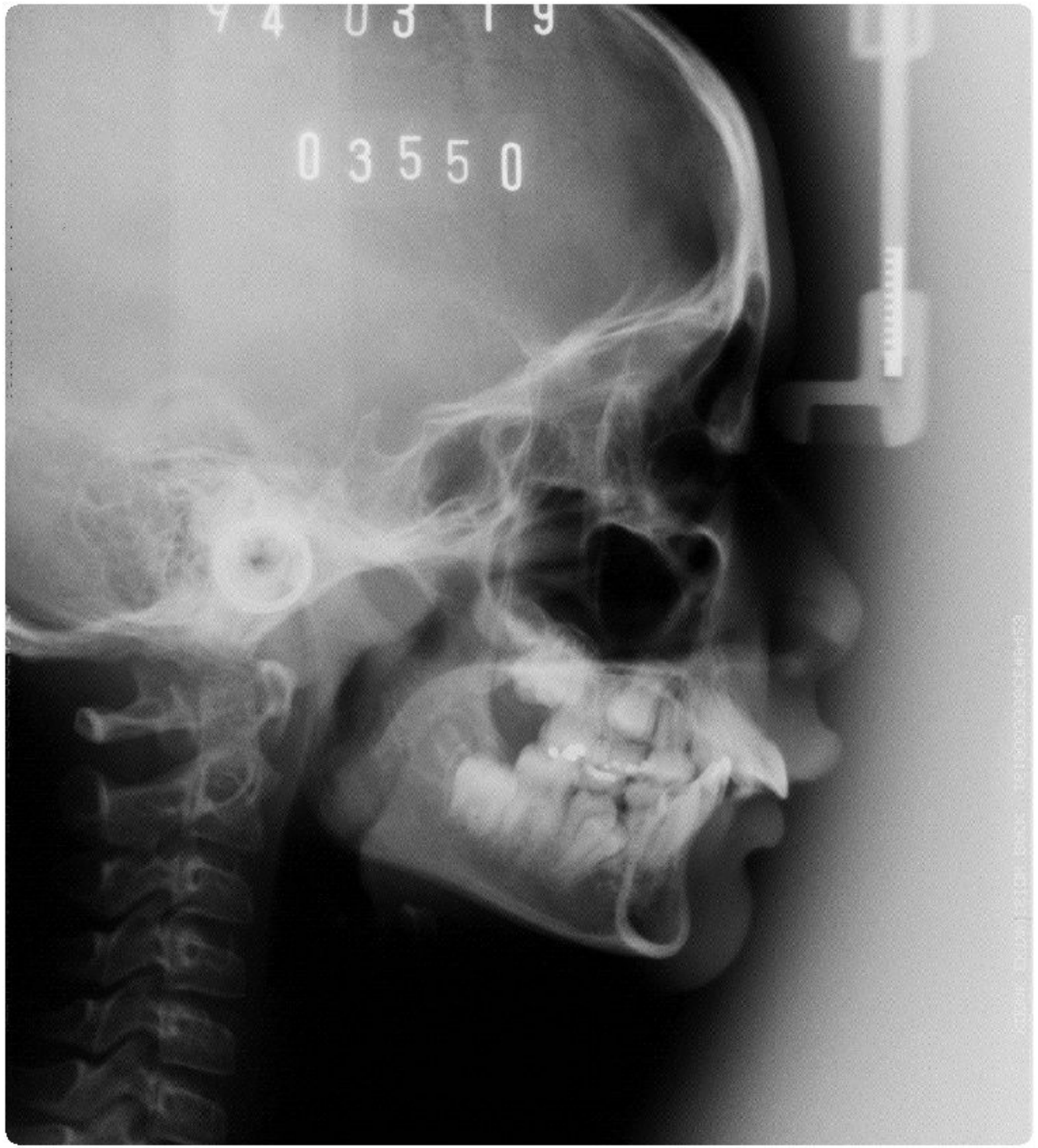

ID# 03232 #4

4-28-05 9-1

ALL TRACINGS AND SUPERIMPOSITIONS MUST BE PRINTED ON TRANSPARENT MEDIA AT THE SAME SCALE AS UNTRACED LATERAL CEPHALOGRAMS

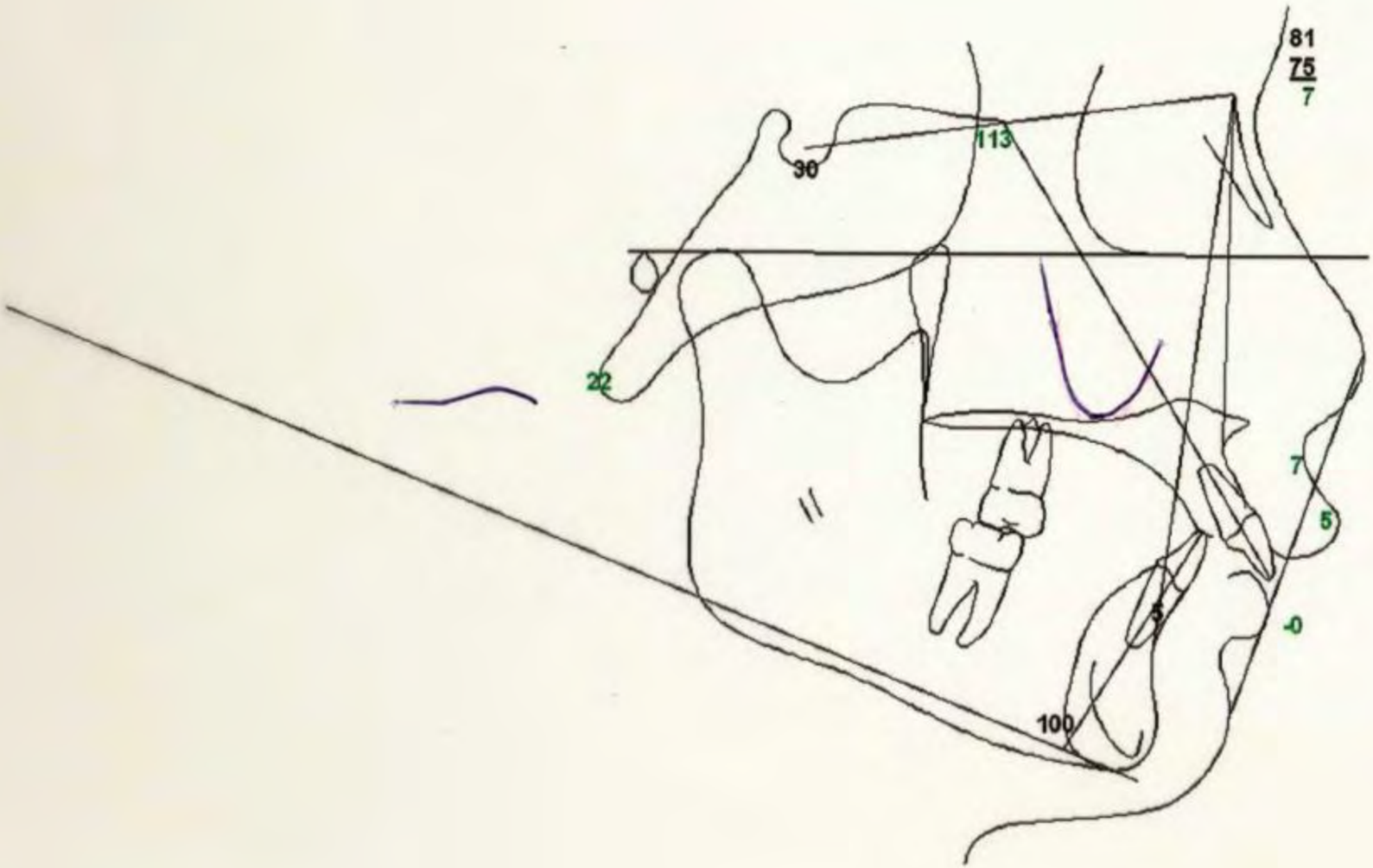

ID# 03232 #4

4-28-05 9-1

ID# 03232 #4

6-2-07 11-2

Digora pct SN40926

Digora pct SN40926

ID# 03232	#4
6-2-07	11-2

Digora pct SN40920
6-2-07
11-2

ALL TRACINGS AND SUPERIMPOSITIONS MUST BE PRINTED ON TRANSPARENT MEDIA AT THE SAME SCALE AS UNTRACED LATERAL CEPHALOGRAMS

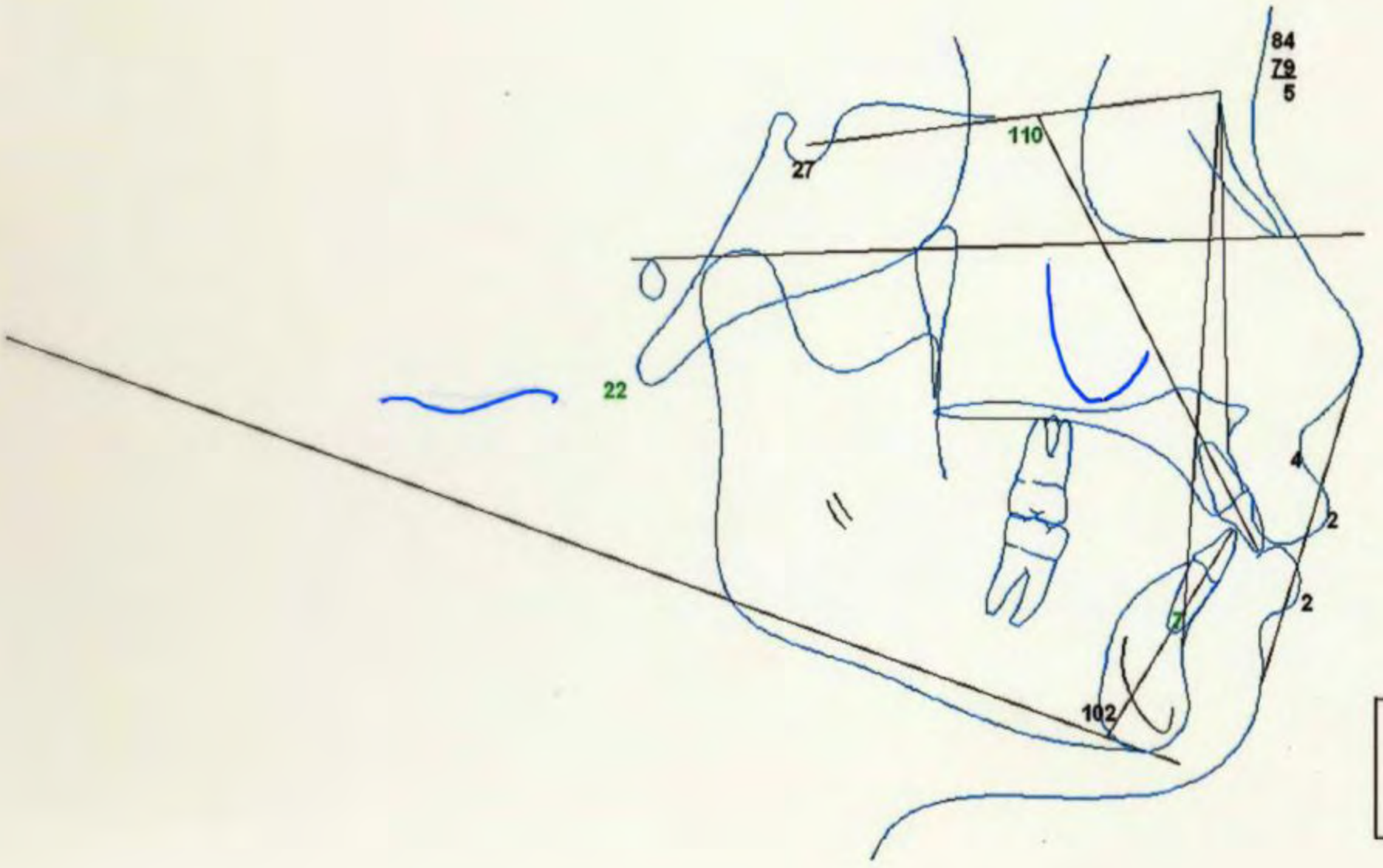

ID# 03232 #4

6-2-07 11-2



ID# 03232 #4

1-30-10 13-10

ID# 03232 #4

1-30-10 13-10

ID# 03232 #4

1-30-10 13-10

ALL TRACINGS AND SUPERIMPOSITIONS MUST BE PRINTED ON TRANSPARENT MEDIA AT THE SAME SCALE AS UNTRACED LATERAL CEPHALOGRAMS

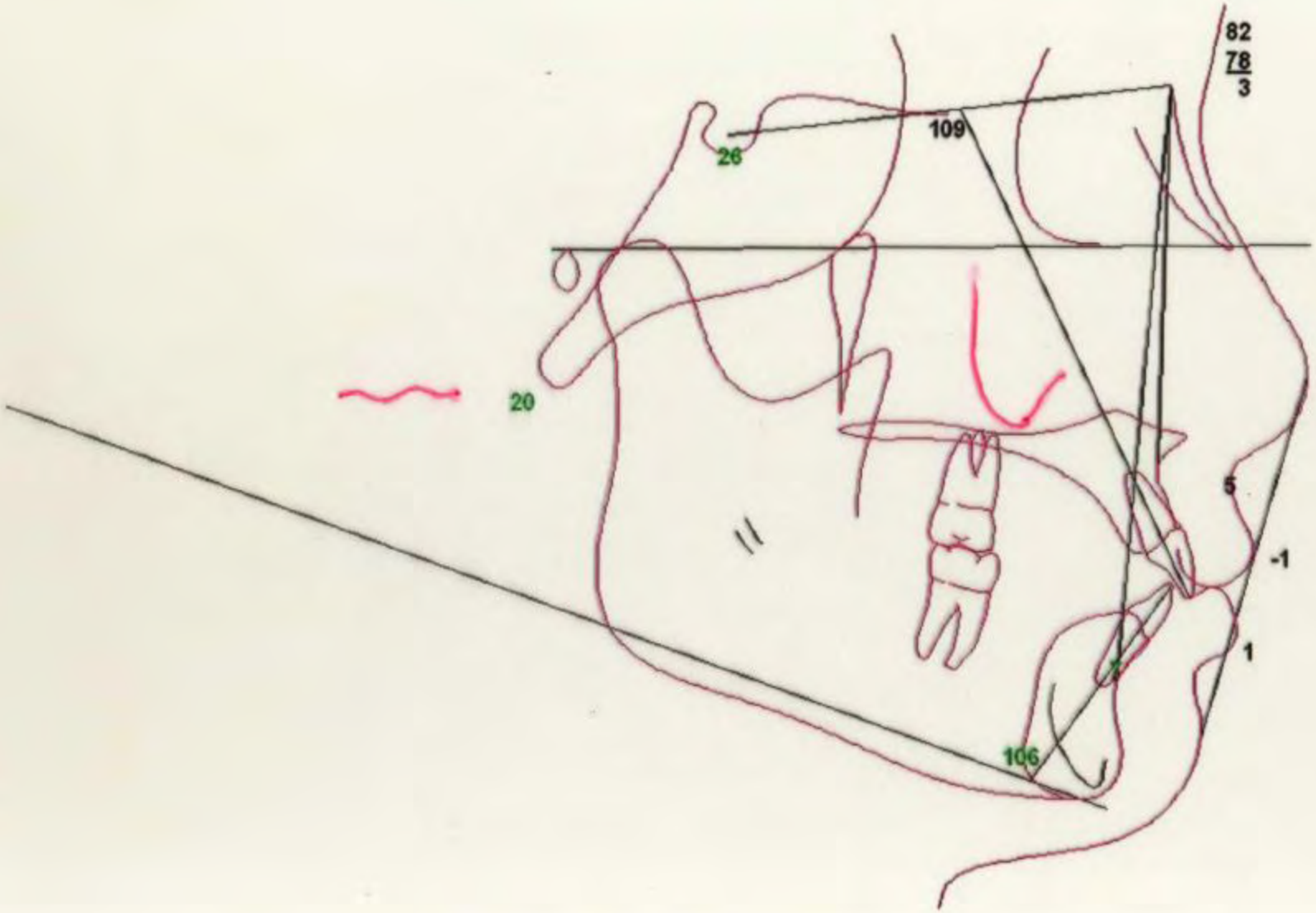

ID# 03232 #4

1-30-10 13-10

ID# 03232 #4

Digitized Lateral Ceph
Digitized Lateral Ceph

9-1
11-2

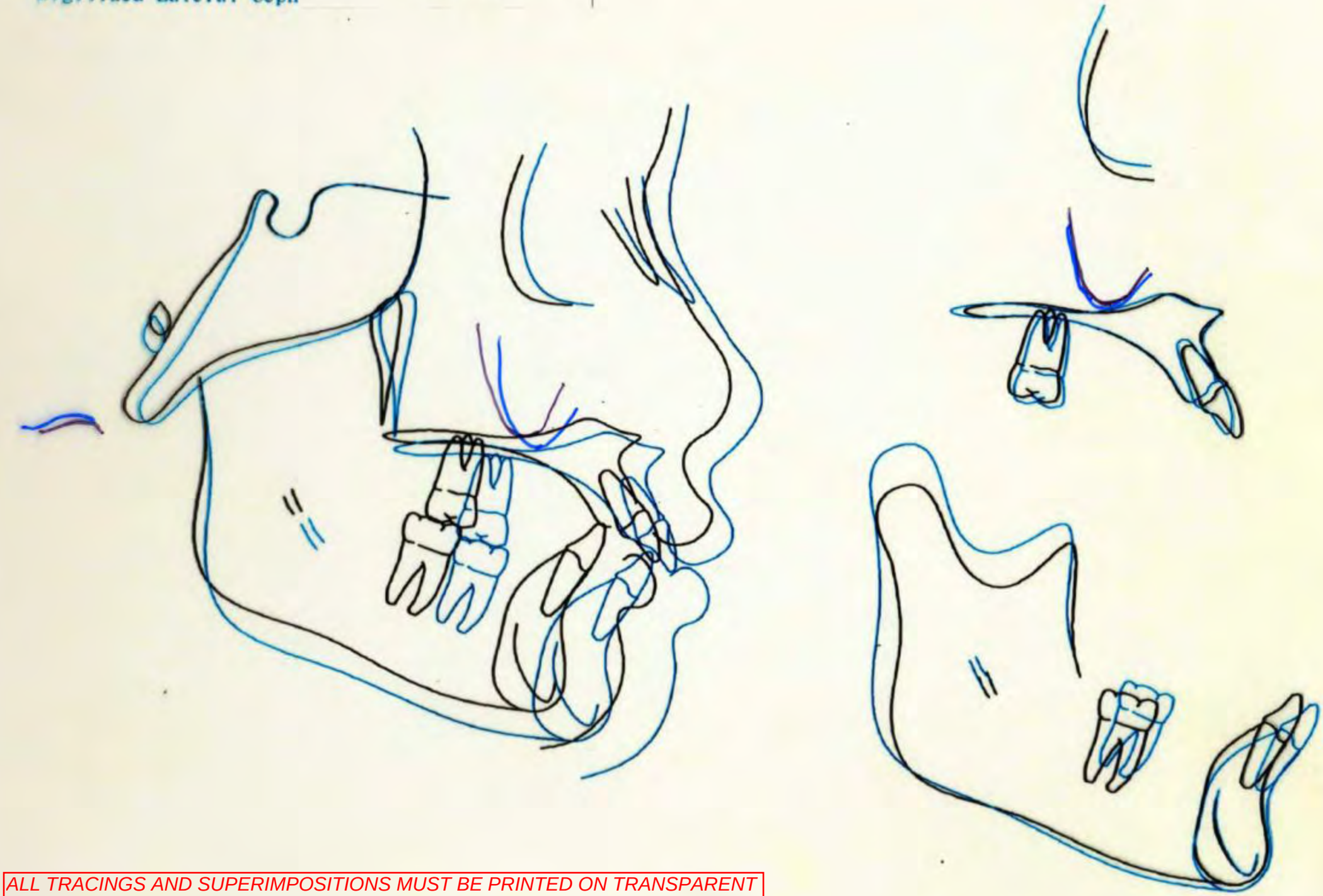

ALL TRACINGS AND SUPERIMPOSITIONS MUST BE PRINTED ON TRANSPARENT MEDIA AT THE SAME SCALE AS UNTRACED LATERAL CEPHALOGRAMS

ID# 03232 #4

Digitized Lateral Ceph
Digitized Lateral Ceph

11-2
13-10

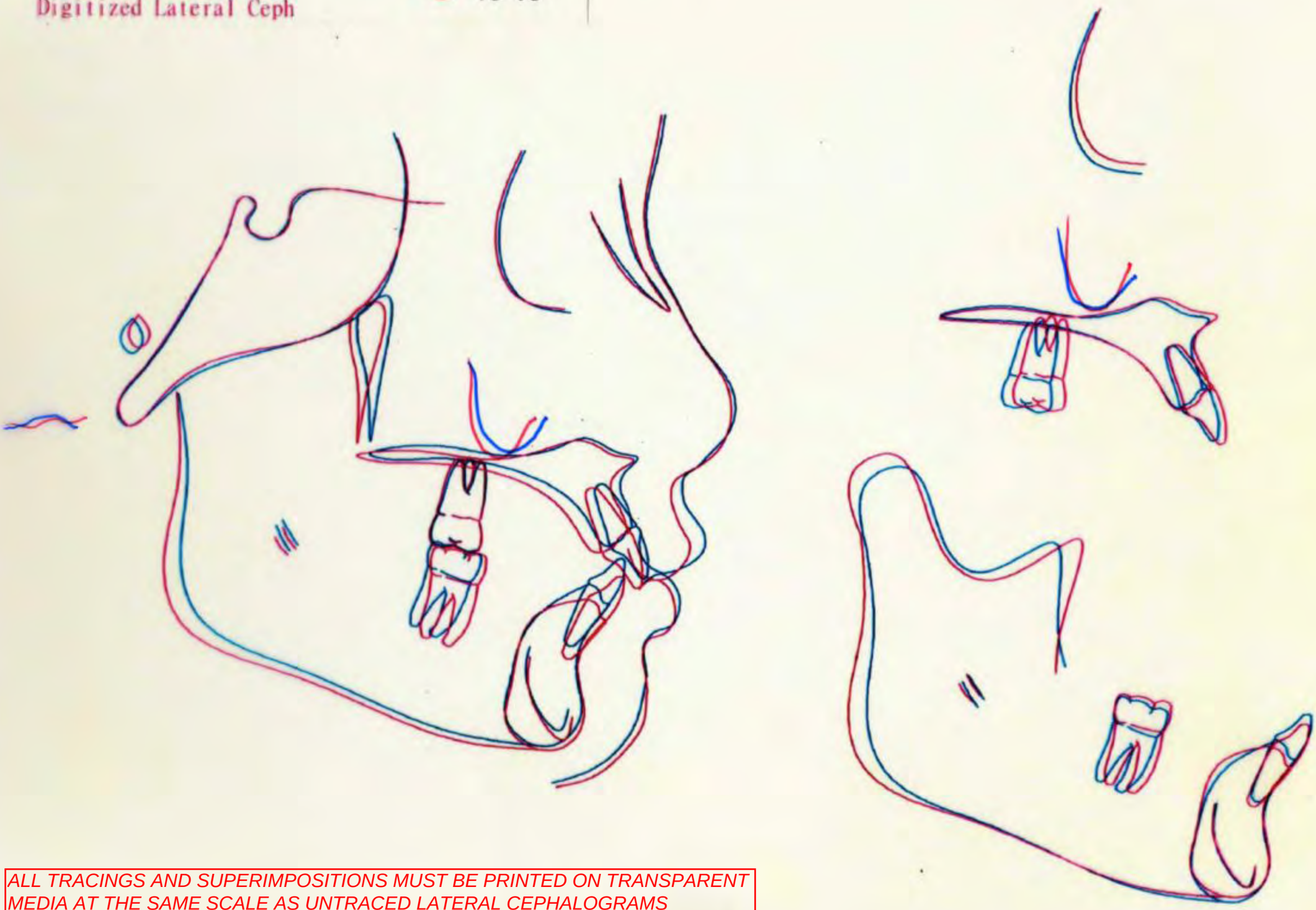

ALL TRACINGS AND SUPERIMPOSITIONS MUST BE PRINTED ON TRANSPARENT MEDIA AT THE SAME SCALE AS UNTRACED LATERAL CEPHALOGRAMS

ID# 03232 #4

9-1
13-10

Digitized Lateral Ceph
Digitized Lateral Ceph

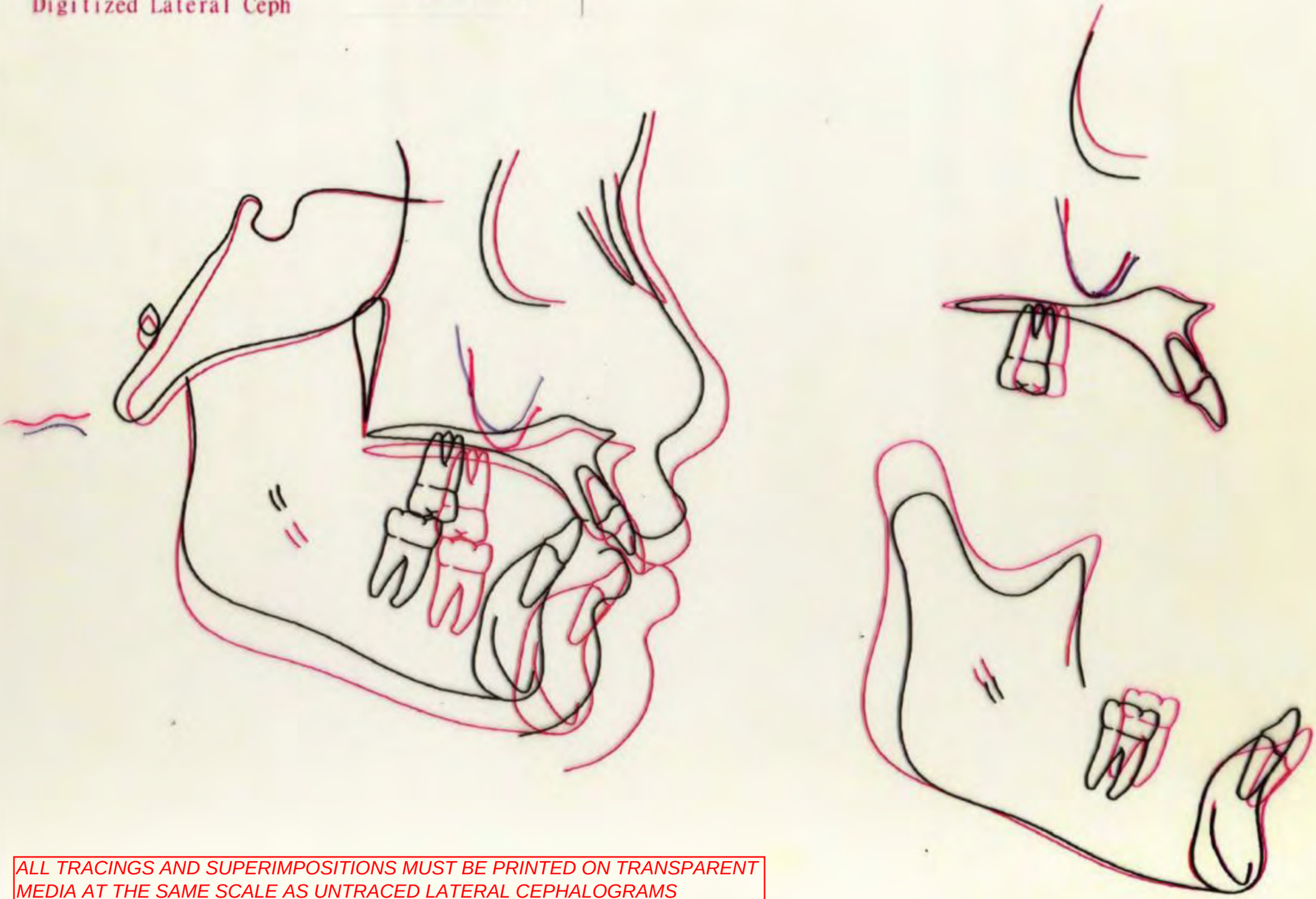

ALL TRACINGS AND SUPERIMPOSITIONS MUST BE PRINTED ON TRANSPARENT MEDIA AT THE SAME SCALE AS UNTRACED LATERAL CEPHALOGRAMS

The American Board of Orthodontics

Clinical Examination Case Report Work File

Version 2010-2011 *What's new in this version?*

Enter required case identification:

ABO ID# 03232

Exam Year 2010

Patient Name Example Case Anna Marie

Case # 4

Instructions:

1. Adobe Reader, Version 8 or later, is required. *(Other PDF Viewers are not fully functional and should not be used; work at the same local hard drive to insure you are always using the same version of Adobe Reader.)*
2. We recommend you use Save-As with a descriptive filename for each case.
3. Enter case report data to this work file at your convenience.
4. In the year prior to your intended clinical exam, register for the exam and you will be informed by email when the ABO electronic submission site is available to you.
5. Login at Online Services – Clinical Exam Electronic Submission.
6. Follow prompts to upload this Case Report Work File, or to enter case reports directly.
7. Your data will be verified against the current year's exam specifications.**
8. You may return to the site to update your data as many times as needed before the submission deadline. You will submit allowable digital models from this site.
9. When finished, mark the reports for each case as Complete and select SUBMIT TO ABO.
10. After submission, use the Print PDF feature to save a read-only copy of your case reports. Print pgs 2-8 and insert in the back pocket of your case report notebook.

** *Currently published ABO exam specifications apply to each year's exam, no matter when the examinee began gathering records. If you upload a former year's Case Report Work File, you will be alerted if any data has not transferred. You are encouraged to login early and verify your case reports against current year specifications.*

7-15-2010

submitted

PATIENT'S NAME:	Example Case Anna Marie		**DOB** (mm-dd-yyyy)	3-15-96
RECORDS SET	**A**	**A1**		**B**
RECORDS DATE (mm-dd-yyyy)	04-28-2005	06-02-2007		01-30-2010
PT. AGE (yy-mm)	9 - 1	11 - 3		13 - 10

	SINGLE PHASE		**PHASE ONE**	**PHASE TWO**
INITIATED TX DATE (mm-dd-yyyy)		**OR**	05-31-2005	07-30-2007
COMPLETED TX DATE (mm-dd-yyyy)			05-25-2006	01-17-2010
CASE CRITERIA IDENTIFIER	Class II Case			
DI VALUE	24	**OR**	**CATEGORY NUMBER**	

HISTORY AND ETIOLOGY: *630 max.*

The patient was a girl, 9 years, 1 month of age with Class II Division 1 malocclusion and a retrognathic mandible. The chief concerns expressed by her mother were her protruding upper incisor and convex profile. She had full-step Class II molar relationships on both sides, 10 mm overjet, and palatally impinging overbite. The clinical examination showed a symmetrical face, incompetent lips, an obtuse nasolabial angle, a convex lateral profile, everted upper lip and a flat chin. The lower facial height was smaller than normal, and the lower lip was trapped behind the maxillary incisors and a pronounced labiomental fold was n

DIAGNOSIS

Skeletal: *360 max.*

A skeletal Class II relationship (ANB angle, 6.5°) due to a retrognathic mandible (SNB angle, 74.5°). Her mandibular angle was average to low.

Dental: *630 max.*

Class II Division 1 malocclusion with full cusp Class II molar relationships on both sides, a 10 mm OJ and a traumatic deep overbite. Palatal indentations were present in the maxillary arch because of the traumatic bite. The lower incisors erupted until they contacted the palate, causing a steep anterior curve of Spee. A transverse deficiency existed at the level of the premolars as a result of the narrow maxillary arch form. There was a lip to palate anterior seal, the soft tissues encouraged upper incisor proclination with the maxillary incisors at 113.1° to SN and 7.5 mm to NA. Mx arch mild spacing/irregular.

Facial: *360 max.*

A symmetrical face, incompetent lips, an obtuse nasolabial angle, a convex lateral profile, everted upper lip and a flat chin. The lower facial height was smaller than normal, and the lower lip was trapped behind the maxillary incisors and a pronounced labiomental fold was noted.

SPECIFIC OBJECTIVES OF TREATMENT

Maxilla (all three planes): *180 max.*

A-P: Normal growth expected Transverse: No skeletal expansion planned
Vertical: Normal growth expected

Mandible (all three planes): *180 max.*

A-P: Normal growth expected (mostly horizontal)
Transverse: Normal growth expected Vertical: Plan to rotate clockwise - increase LFH

Maxillary Dentition

A-P: *180 max.*

6's - expect normal development Incisors: to NA: retract ~ 2-3 mm, , to SN: upright ~ 4-5 degs
Establish ideal OJ and OB

Sample

Vertical: *180 max.* **-1102 characters remaining**

Hold max 6's - maximum

Intermolar Width: *90 max.*

Expand 3.0 mm + rotate molars

Mandibular Dentition

A-P: *180 max.*

Normal growth expected. Incisors: to NB: (labial) ~ 2.0 mm to MP: (labial) ~ 5-6 degs
Establish ideal OJ and OB

Vertical: *180 max.*

Extrude 6's ~ 3-4 mm. Intrude incisors ~ 3.0 mm

Intermolar / Intercanine Width: *180 max.*

Intermolar (measured at the gingival margin below buccal groove)-increase by molar uprighting. Intercanine width: (between cusp tips): No change intercanine width.

Facial Esthetics: *270 max.*

A-P: Reduce facial convexity, retract upper lip 4.0 mm, Increase chin projection (growth)
Vertical: Increase LFH, Reduce lip incompetence, increase smile arc
Transverse: Smile esthetics-Improve upper lip to upper incisor relationship, maintain broad arch form

TREATMENT PLAN: *1170 max.*

1. Deliver a removable appliance to align and retract the upper incisors.
2. Use the twin block appliance to correct Class II skeletal growth pattern.
3. If the result of the first stage is adequate, edgewise fixed appliances would be used to achieve a functional occlusion after second molars erupt.
4. If dental Class II discrepancy is not completely resolved or facial profile improvement is not satisfied after orthopedic correction, extraction treatment might be performed
5. If the result of the first stage is not good enough to obtain a functional occlusion or an acceptable profile with orthodontic treatment alone, the patients growth would be observed until the end of growth, and orthodontic treatment would be combined with orthognathic surgery to finish the occlusion.
6. Retain with upper Hawley retainers and lower bonded 3-3 retainers

APPLIANCES AND TREATMENT PROGRESS: *990 max.*

The alignment and retraction of the upper arch with a removable appliance was performed. This change made it possible to use the Twin-block appliance. The patient was instructed to wear the appliance for 24 hours per day (with the exception of contact sports and swimming) and while eating. In the appointment after the twin block was delivered, aggressive contouring of the appliance was initiated to reduce the deep overbite. Because the initial bite registration had been obtained using a •step-by step? protocol, the Twin block was reactivated 2 months after appliance delivery. After the overjet had been fully reduced, the patient was fitted with a retainer with a steep inclined biteplane. After reducing the anteroposterior skeletal discrepancy and second molars erupted, both arches were fully banded and bonded with edgewise fixed appliances. The patient progressed through a routine archwire sequence. Class II elastics and the Forsus device were worn full time for nearly 6 mo.

RESULTS ACHIEVED

If differing radiographic units preclude superimposition(s) – check here ☐

Maxilla (all three planes): *180 max.*

A-P: Normal growth expressed
Transverse: No skeletal expansion planned Vertical: Normal growth expressed

sample

Mandible (all three planes): *180 max.*

A-P: Normal growth expressed-good condylar growth (horizontal) Transverse: Transverse growth expressed
Vertical: Normal growth expressed

Maxillary Dentition

A-P: *180 max.*

Normal growth expressed. Good incisor torque was achieved. Retracted incisors ~ 4.0 degs to SN and 2.0 mm to NA. Class I molar and cuspid with ideal overjet and overbite achieved.

Vertical: *180 max.*

Normal growth expressed. Molars: Held Incisors: Extruded 1.0 mm

Intermolar Width: *90 max.*

Intermolar width increased by 3.3 mm. Intercanine width: no change

Mandibular Dentition

A-P: *180 max.*

AP: Incisor to MP: moved labial from 100.1° to 106.0° and tipped ~ 1.9 mm to NB.
Mandible movement/mandibular growth to achieve Class I molar and cuspid.

Vertical: *180 max*.

The incisors intruded 5.0 mm. Molars extruded 4.0 mm (obtain bite opening= gwth + elastic wear/Forsus) The curve of Spee was reduced.

Intermolar / Intercanine Width: *180 max.*

The intermolar width increased 1.3 mm as planned. The intercanine width: no change

Facial Esthetics: *270 max.*

Reduced facial convexity - growth. Increase chin porjection - growth. Retract U Lip ~ 3.0 mm.
Reduce lip incompetence, increase LFH, increased incisor display, increased smile arc.

RETENTION: *630 max.*

The patient was instructed to wear the tooth positioner for 1 month. After this, MX Hawley will be delivered. Mandibular fixed (bonded) 3 x 3 will be placed and patient will be instructed to wear it indefinitely. The third molars were evaluated, and the patient was informed that they might be removed in the future.

FINAL EVALUATION OF TREATMENT: *1170 max.*

The facial changes produced as a result of treatment were directly related to skeletal and dentoalveolar alterations that were planned as treatment goals for the patient. Ideal occlusion was achieved in a severe Class II deep overbite malocclusion with favorable growth. More increase in the mandibular length when compared with the maxilla was achieved on the basis of the differential changes. The prolonged treatment time was expected, based on the severity of the problem and the two phases of treatment required to obtain total correction of the dentoskeletal discrepancy. Some side effects resulted from the prolonged elastic and Forsus device wear. The patient is pleased with her dental and facial esthetics. The retraction of maxillary incisors would have resulted in undesirable profile flattening with extraction.

EXAM YEAR 2010 **ABO DISCREPANCY INDEX Version 2010-2011**
ABO ID # 03232 **CASE#** 4 Example Case Anna Marie

TOTAL D.I. SCORE 24

Examiners will verify measurements in each parameter.

OVERJET

0 – 0.9 mm. (edge-to-edge)	= 1 pt.	
1 – 3 mm.	= 0 pts.	
3.1 – 5 mm.	= 2 pts.	
5.1 – 7 mm.	= 3 pts.	
7.1 – 9 mm.	= 4 pts.	
> 9 mm.	= 5 pts.	
Negative Overjet (x-bite):		
1 pt. per mm. per tooth	= ___pts.	
Total		5

OVERBITE

0 – 3 mm.	= 0 pts.	
3.1 – 5 mm.	= 2 pts.	
5.1 – 7 mm.	= 3 pts.	
Impinging (100%)	= 5 pts.	
Total		5

ANTERIOR OPEN BITE

0 mm. (edge-to-edge), 1 pt. per tooth	=___pts.	
then 1 pt. per additional full mm. per tooth	=___pts.	
Total		0

LATERAL OPEN BITE

2 pts. per mm. per tooth

Total 0

CROWDING (only one arch)

0 – 1 mm.	= 0 pts.	
1.1 – 3 mm.	= 1 pts.	
3.1 – 5 mm.	= 2 pts.	
5.1 – 7 mm.	= 4 pts.	
> 7 mm.	= 7 pts.	
Total		1

OCCLUSION

Class I to end on	= 0 pts.	
End-to-End Class II or III	= 2 pts. per side	___pts.
Full Class II or III	= 4 pts. per side	8 pts.
Beyond Class II or III	= 1 pt. per mm additional	1 pts.
Total		9

LINGUAL POSTERIOR X-BITE

1 pt. per tooth Total 0

BUCCAL POSTERIOR X-BITE

2 pts. per tooth Total 0

CEPHALOMETRICS (See Instructions)

ANB ≥6° or ≤ -2°	@ 4 pts. =	4
Each degree > 6°	___x 1 pt. =	
Each degree < -2°	___x 1 pt. =	
SN-MP		
≥ 38°	@ 2 pts. =	
Each degree > 38°	___x 2 pts. =	
≤26°	@ 1 pt. =	
Each degree < 26°	___x 1 pt. =	
$\bar{1}$ to MP ≥ 99°	@ 1 pt. =	
Each degree > 99°	___x 1 pt. =	
Total		4

OTHER (See Instructions)

Supernumerary teeth	___x 1 pt. =	
Ankylosis of perm. Teeth	___x 2 pts. =	
Anomalous morphology	___x 2 pts. =	
Impaction (except 3rd molars)	___x 2 pts. =	
Midline discrepancy (>3 mm)	@ 2 pts. =	
Missing teeth (except 3rd molars)	___x 1 pt. =	
Missing teeth, congenital	___x 2 pts. =	
Spacing (4 or more, per arch)	___x 2 pts. =	
Spacing(mx cent diastema > 2 mm)	@ 2 pts. =	
Tooth Transposition	___x 2 pts. =	
Skeletal asymmetry(nonsurgical tx)	@ 3 pts. =	
Addl. treatment complexities	___x 2 pts. =	

Identify:

Total Other 0

submitted

INSTRUCTIONS: Second molars should be in occlusion. Mark extracted teeth with a check in the bolded box. Place score beside each deficient tooth.

Total C-R Eval Score: 12

Alignment/Rotations 1

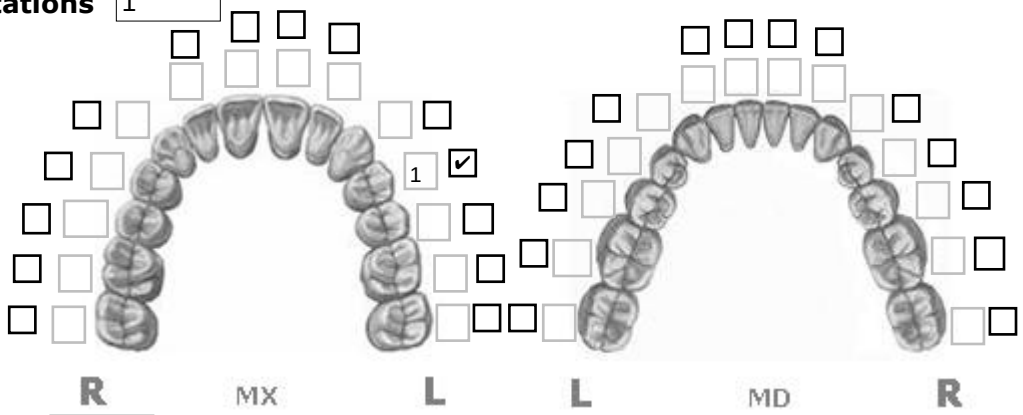

Marginal Ridges 2

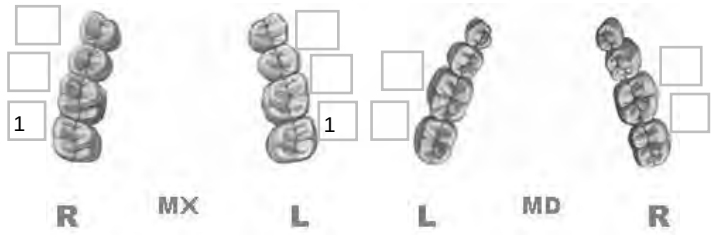

Buccolingual Inclination 1

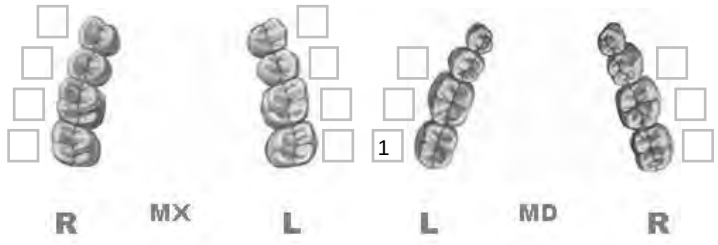

Overjet 3

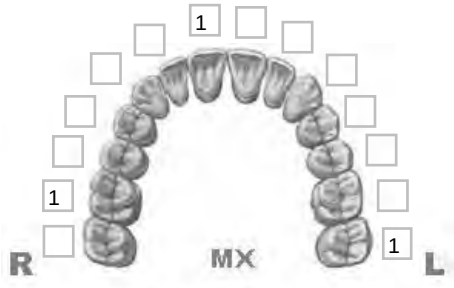

submitted

Occlusal Contacts 0

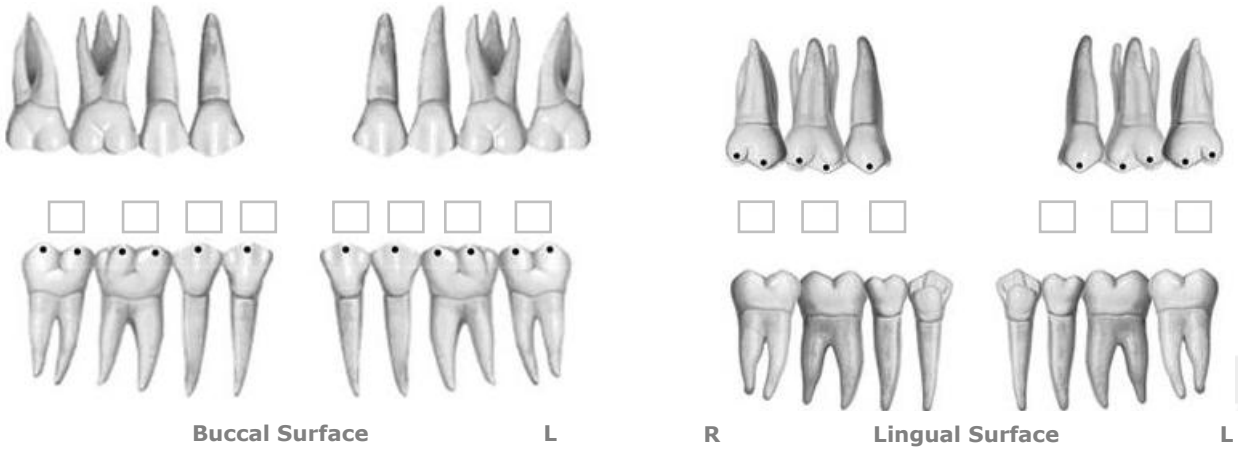

Occlusal Relationships 3

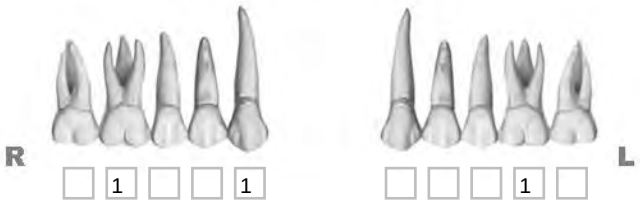

Interproximal Contacts 0

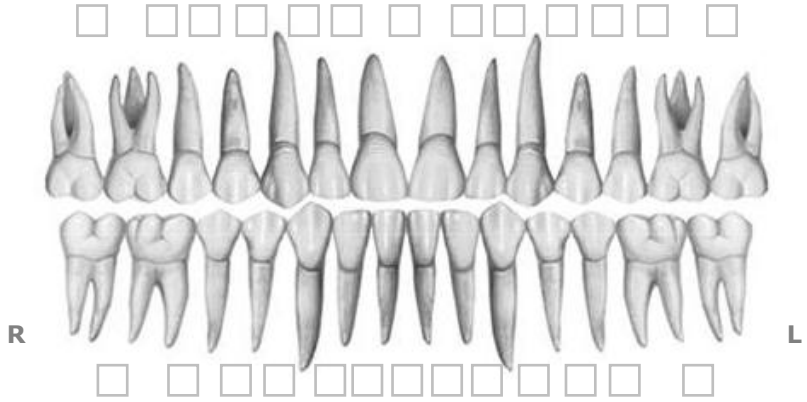

Root Angulation 2

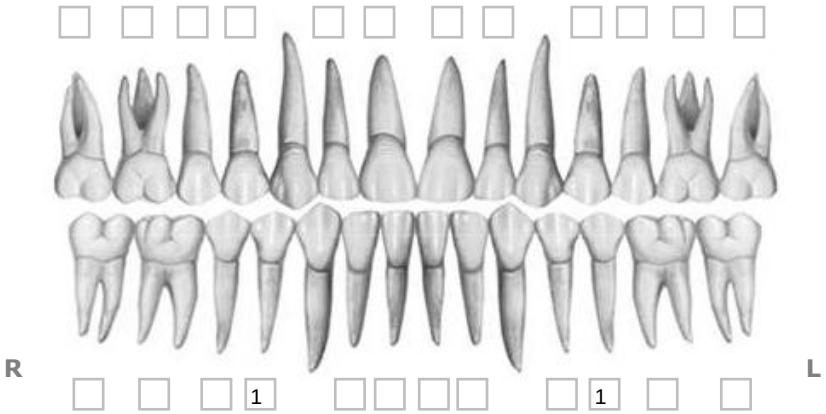

submitted

Examiners will evaluate treatment objectives and results, in addition to doing a Records Analysis and Overall Analysis.

MEASUREMENTS

SCORING

SKELETAL ANALYSIS (S)

0-Acceptable 1-Unacceptable

CEPHALOMETRIC

	PRE TX A	PROG A1	POST TX B	DIFF. |A-B|
SNA°	81.1	83.9	81.6	0.5
SNB°	74.5	78.7	78.4	3.9
ANB°	6.5	5.2	3.2	3.3
SN-MP°**	29.9	27.4	26.3	3.6
FMA°	22.2	21.9	20.3	1.9

	EXAMINEE TX OBJECTIVES	PRE TX OBJ	POST TX RESULT	Score
A-P MX	Normal growth expected	○ 0 ○ 1	○ 0 ○ 1	0
A-P MN	Normal growth expected (mostly horizontal)	○ 0 ○ 1	○ 0 ○ 1	0
VERT MX	Normal growth expected	○ 0 ○ 1	○ 0 ○ 1	0
VERT MN	Plan to rotate clockwise - increase LFH	○ 0 ○ 1	○ 0 ○ 1	0

DENTAL ANALYSIS (D)

1 TO NA mm	7.5	4.4	5.5	2.0
1 TO SN°	113.1	109.5	108.8	4.3
1 TO NB mm	4.8	6.8	6.7	1.9
1 TO MP°	100.1	101.7	106	5.9

A-P MX	Incisors: retract and upright Molars: Hold 6's - moderate	○ 0 ○ 1	○ 0 ○ 1	0
A-P MN	Incisors: Adv/flare Molars: Expect normal growth - no anchorage planned	○ 0 ○ 1	○ 0 ◉ 1	1
VERT	Incisors: MX-hold MN: intrude Molars: MX-hold MN: extrude	○ 0 ○ 1	○ 0 ○ 1	0

ARCH

6 TO 6 WIDTH	43.5	43.5	46.8	3.3
6 TO 6 WIDTH	50	49	51.3	1.3
3 TO 3 WIDTH	26.5	25.6	26.5	0.0
CURVE OF SPEE	4.1	4.5	1.6	2.5
MANDIBULAR ARCH FORM	OV	OV	OV	SAME

TRANS MX	Increase as a result of molar uprighting/rotation	○ 0 ○ 1	○ 0 ○ 1	0
TRANS MN	Increase as a result of molar uprighting/rotation	○ 0 ○ 1	○ 0 ○ 1	0
TRANS ANT	No change	○ 0 ○ 1	○ 0 ○ 1	0
CURVE OF SPEE	Decreased	○ 0 ○ 1	○ 0 ○ 1	0
ARCH FORM MN	No change	○ 0 ○ 1	○ 0 ○ 1	0

FACIAL ANALYSIS (F)

E-LINE	Upper	4.9	2.2	-0.6	5.5
	Lower	-0.1	1.5	0.8	0.9

FACIAL ESTHETICS	Reduced facial convexity	○ 0 ○ 1	○ 0 ○ 1	0

S-D-F Subtotal 1

RECORDS ANALYSIS

Shaded areas for examiner only.

	FACIAL PHOTOS	INTRAORAL PHOTOS	INTRAORAL RADIOGRAPHS	CEPH. & TRACINGS	COMP. TRACING	DENTAL CASTS	CASE REPORT	PRESENT. QUALITY	
PRE-TX A &/OR PROG. A1	0 1	0 1	0 1	0 1		0 1	0 1	0 1	
FINAL B	0 1	0 1	0 1	0 1	0 1	0 1	0 1	0 1	SUB-TOTAL RECORDS ANALYSIS

OVERALL ANALYSIS

TREATMENT PLANNING / MECHANOTHERAPY				FINAL TREATMENT RESULTS				
0 ACCEPT	1	2	3 DEFICIENCIES	0 ACCEPT	1	2	3 DEFICIENCIES	SUB-TOTAL OVERALL ANALYSIS

TOTAL