


Scenario-based Clinical Exam




Cast Radiograph Evaluation (CRE)/
Case Management Form (CMF)/
Superimposition
Preparation Materials &
Sample Cases

(Rev. 5.08.2024)

Disclaimer

- The following sample questions and answers were composed and vetted by a panel of experts in orthodontics and are intended to provide a guide of the types of cases and questions that make up the actual scenario-based clinical examination.
 - After the examination, trained examiners, who are all in-good-standing board certified orthodontists, will score the typed responses using rubrics as guides to their decision making.
 - Rubrics help to create consistency in the decisions the examiners make while grading an examinees typed responses. The rubrics are not absolute, as there may be other acceptable answers that are not listed. However, no credits will be awarded for answers not included in the rubrics.
- 

Disclaimer Continued

- The ABO has developed multiple versions of the case-based scenario examination to be used during a test administration cycle. Although the set of cases and questions used on the different versions will not all be the same, all versions follow the same content framework as defined by the practice analysis study.
 - Scores will be computed using psychometric equating procedures to ensure that all versions are of the same difficulty level.
 - Review of these sample cases does not guarantee that a candidate will pass the examination.
 - Examinee responses to exam questions will be typed out and should be in numbered list format (i.e., short and concise, no essay responses).
- 



Cast-Radiograph Evaluation (CRE)

For the Cast-Radiograph Evaluation (CRE), examinees will be shown a series of records which may include: photo montage, images of models, and/or panoramic radiographs (as needed). Examinees will be asked to answer questions based on the information provided.

- While examinees are not required to grade models or memorize the specific CRE parameters for each measurement, examinees will need to be familiar with the use of the CRE to assess treatment outcomes.
- Examinees need to be prepared to answer some specific critical thinking questions related to the different CRE parameters.

CRE Sample Case

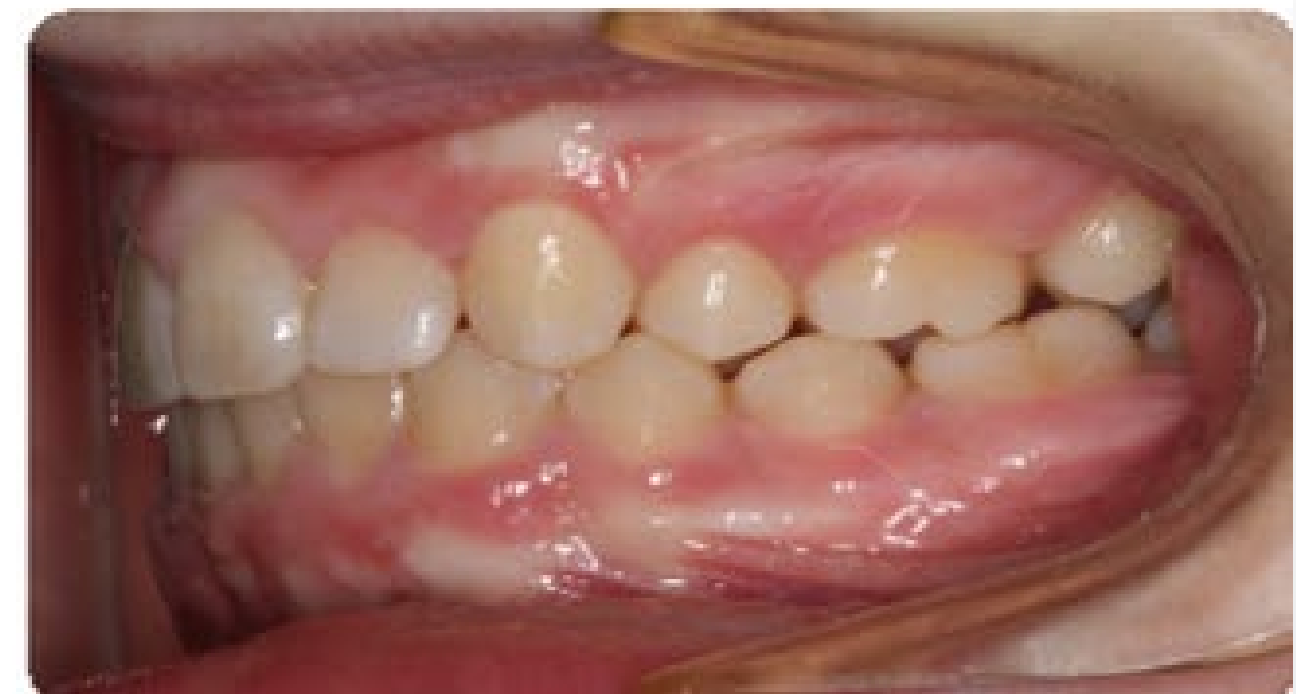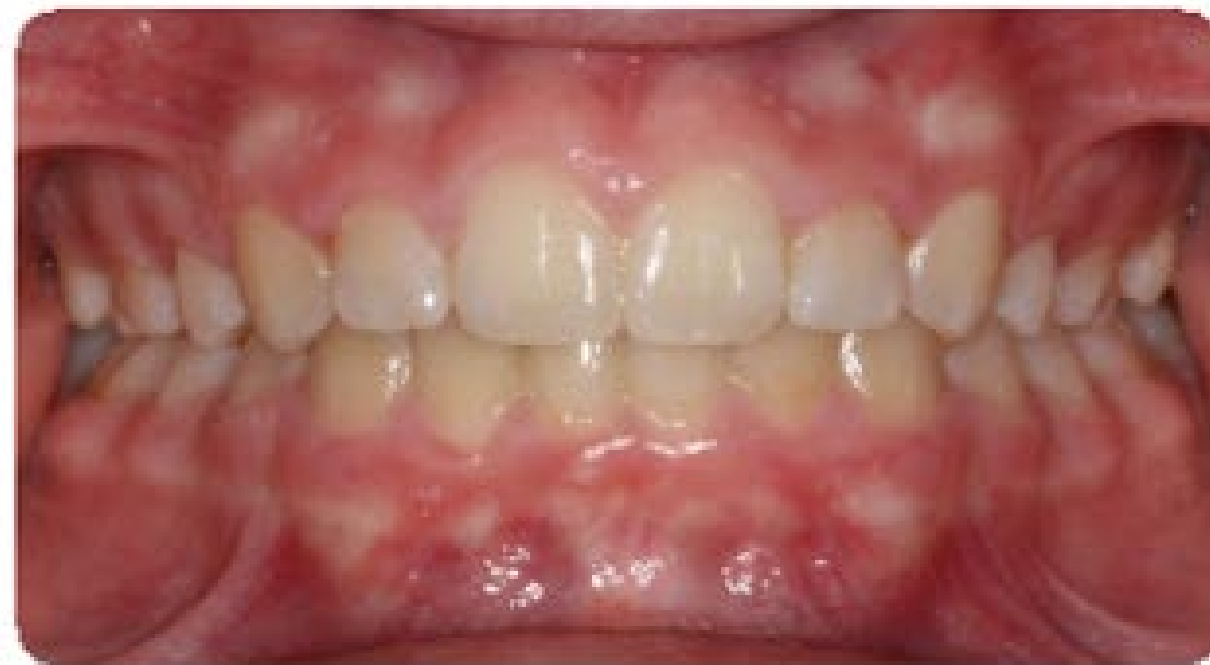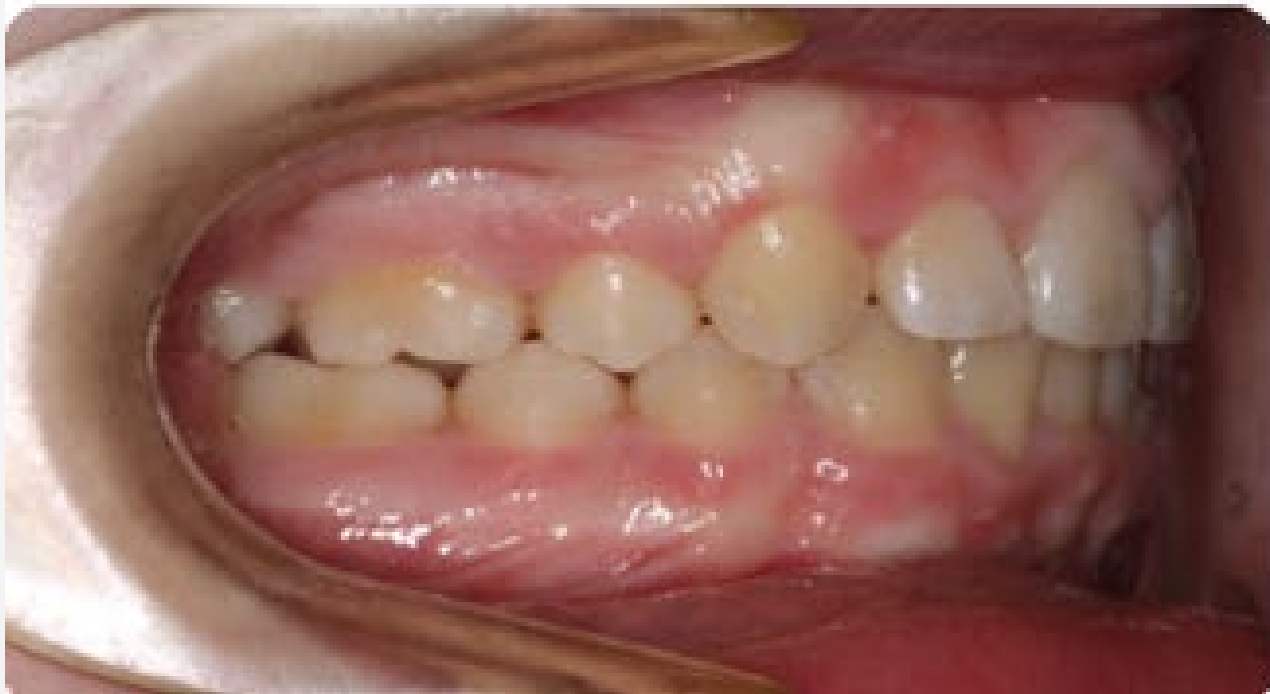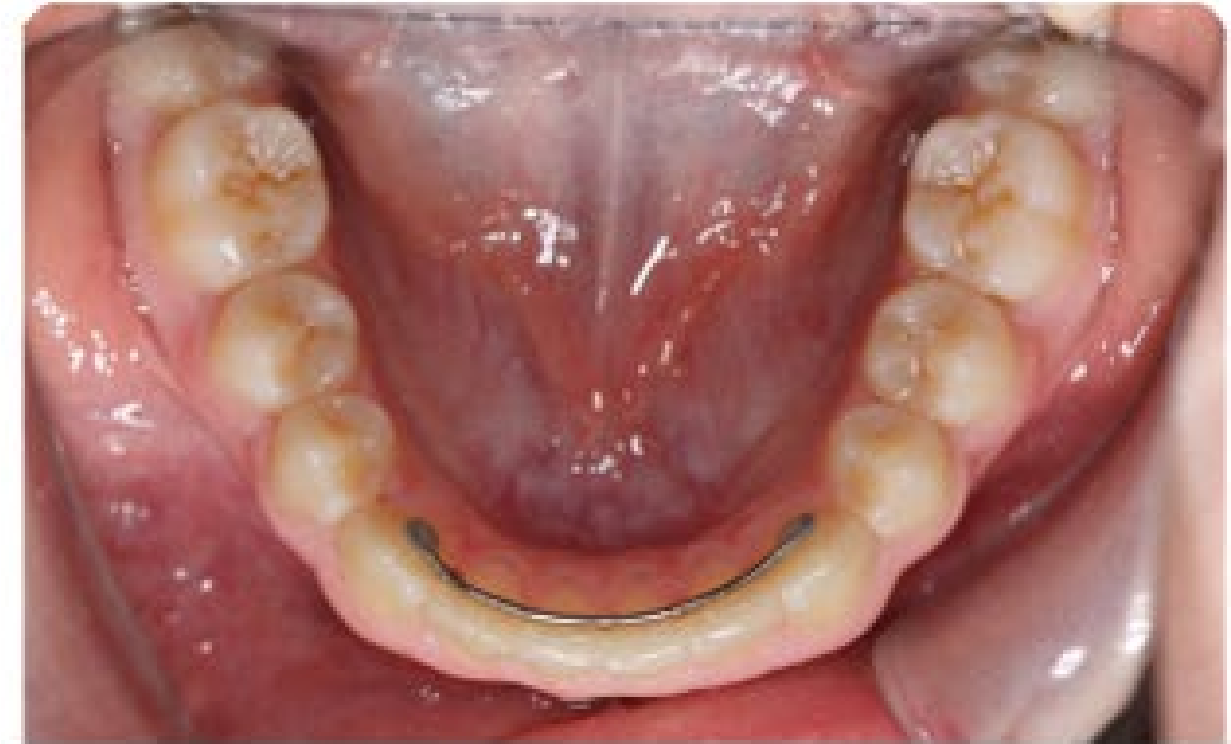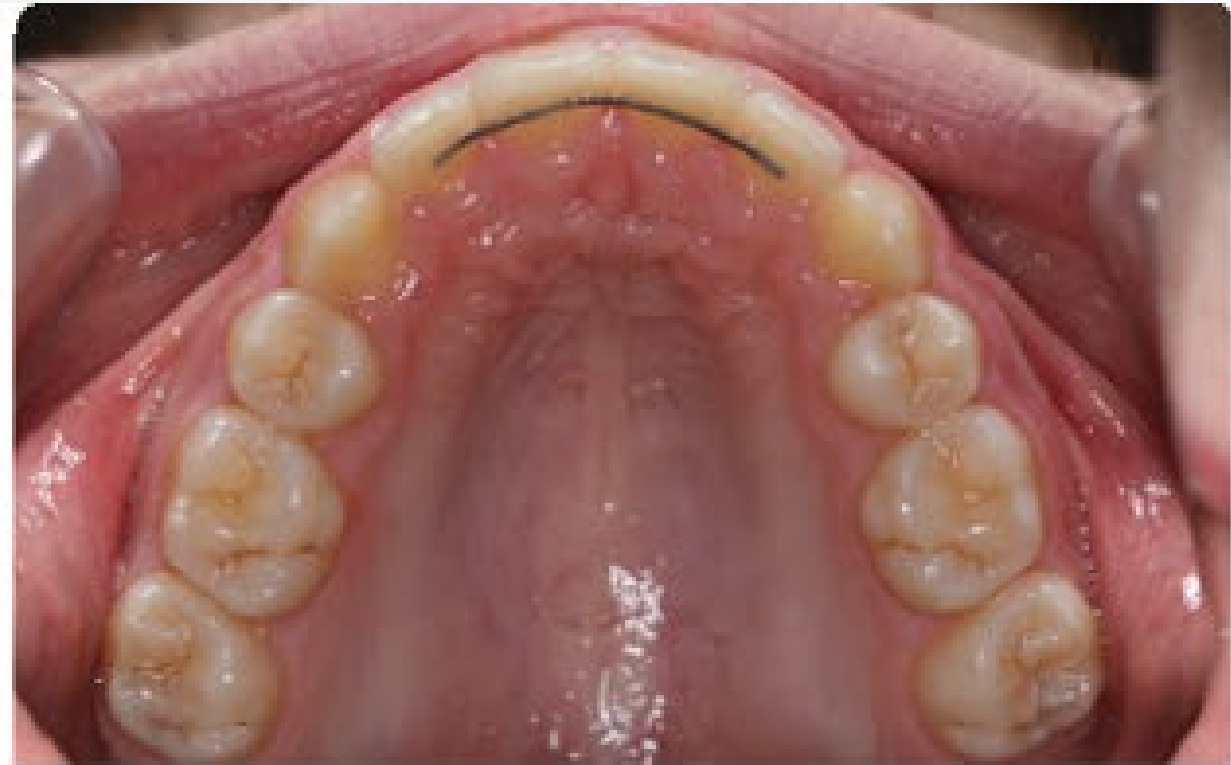Question 1

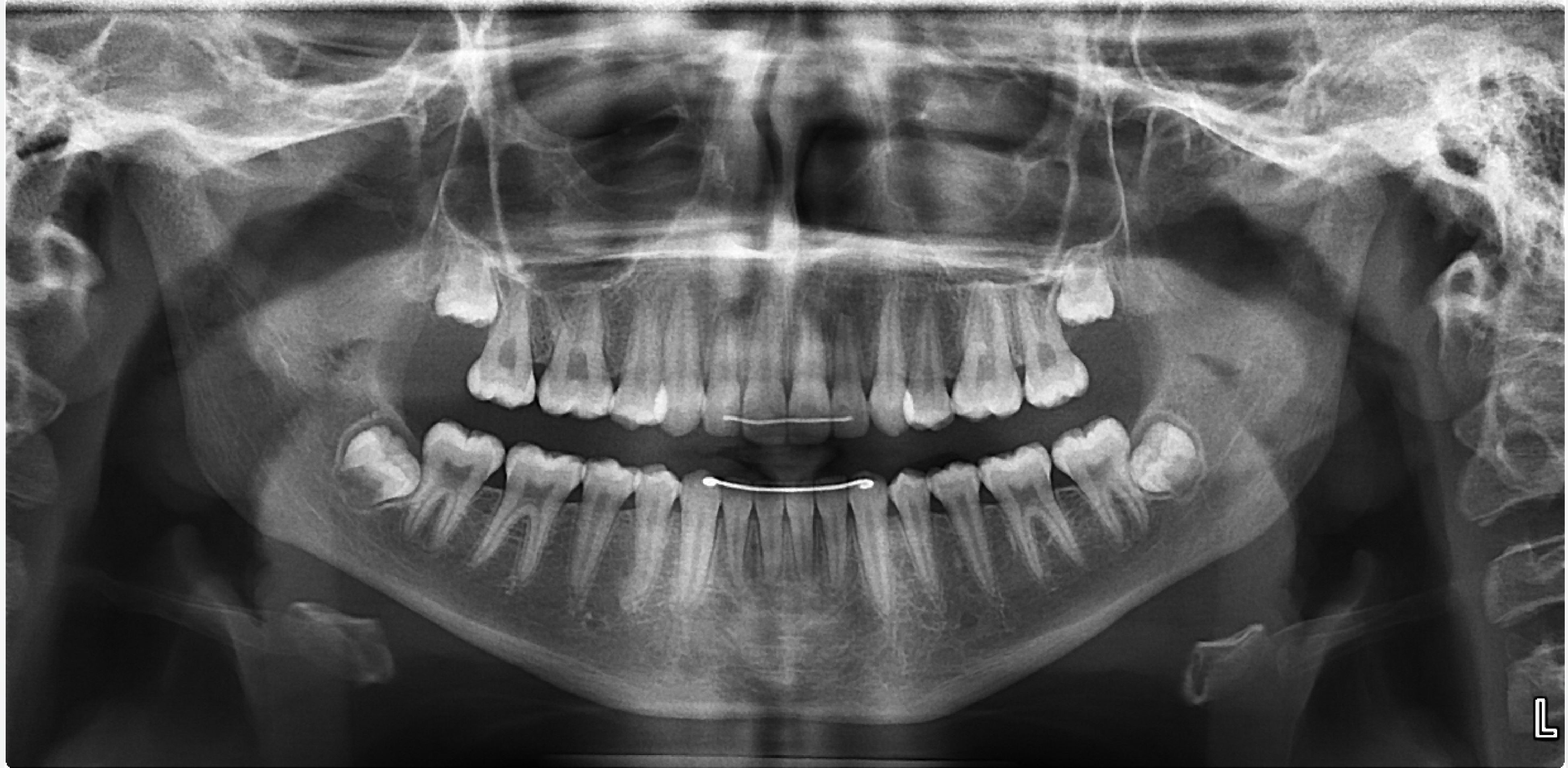Classification

Domain 4: Critical Analysis and Outcomes Assessment

Prompt

When evaluating the final intraoral pictures and the panoramic radiograph of this case, what steps should have been taken to improve the CRE score of 30 for this patient? Please respond in numbered list format below.





CRE Sample Case

Question 1

Classification

Domain 4: Critical Analysis and Outcomes Assessment

Prompt

When evaluating the final intraoral pictures and the panoramic radiograph of this case, what steps should have been taken to improve the CRE score of 30 for this patient? Please respond in numbered list format below.

CRE Sample Case

Question 1

Fully Proficient Model Response

The examinee's response must include five of the following:

1. Improve maxillary anchorage to control maxillary molar A-P position (loss of anchorage resulted in a super Class II molar)
2. Maxillary expansion to improve posterior overjet (inadequate posterior OJ)
3. Archwire bends or bracket/band reposition to correct marginal ridge discrepancy between maxillary first and second molars.
4. Archwire bends or bracket/band reposition to achieve proper occlusal contacts (or allow posterior settling)
5. Correct rotation or second order bend between maxillary right cuspid and lateral incisor
6. Close all posterior interproximal spaces

CRE Sample Case

Question 1

Borderline Proficient Model Response

The examinee's response must include four of the above:

Not Proficient Model Response

The examinee's response include three of the above:



Case Management Form (CMF)

Case Management Form (CMF)

Reasons for the ABO Case Management Form

1. Self evaluation (quantified)
2. Evaluation/judgement of each parameter (quantified)
3. Evaluation of records (quantified)
4. Scores can be scored/digitally retrieved (demonstrates trends)
 - A numerical VTO
 - Self evaluation
 - Monitors record quality

Case Management Form (CMF)

		MEASUREMENTS		SKELETAL	
		PRE TX	PROG	POST TX	DIFF.
		A	A1	B	A-B
CEPHALOMETRIC	SNA°				0.0
	SNB°				0.0
	ANB°				0.0
	SN-MP°**				0.0
	FMA°				0.0
		DENTAL			
ARCH	<u>1</u> TO NA mm				0.0
	<u>1</u> TO SN°				0.0
	<u>-1</u> TO NB mm				0.0
	<u>-1</u> TO MP°				0.0
ARCH	<u>6</u> TO <u>6</u> WIDTH				0.0
	<u>6</u> TO <u>6</u> WIDTH				0.0
	<u>3</u> TO <u>3</u> WIDTH				0.0
	CURVE OF SPEE				0.0
	MANDIBULAR ARCH FORM				
		FACIAL			
E-LINE	Upper				0.0
	Lower				0.0

CMF Sample Case

Question 1

- The examinee will have access to the following records: Initial photo montage, initial intraoral photographs, initial lateral cephalogram, initial cephalometric tracing, and the pre-treatment skeletal analysis (see example below).

	PRE TX A
SNA°	81.0
SNB°	72.0
ANB°	9.0
SN-MP ^{o**}	48.0
FMA°	39.0

CMF Sample Case

Question 1

Classification

Domain 2: Treatment Objectives and Planning

Opening Scenario

A 16-year, 2-month-old female presents with the chief complaint that “My teeth stick out.”

Prompt

Using the lateral cephalometric analysis and the CMF chart, identify appropriate skeletal treatment objectives. Please respond in numbered list format below.

Model Responses

The board expects a fully proficient response for this question to include:

1. Increase SNB
2. Decrease ANB
3. Decrease SN-MP
4. Decrease FMA

CMF Sample Case

Question 2

- The examinee will have access to the following records: Initial photo montage, initial intraoral photographs, initial lateral cephalogram, initial cephalometric tracing, final photo montage, final intraoral photographs, final lateral cephalogram, final cephalometric tracing, and the pre- /post-treatment skeletal analysis (see example below).

	PRE TX A	PROG A1	POST TX B	DIFF. A-B
SNA°	81.0		81.0	0.0
SNB°	72.0		70.0	-2.0
ANB°	9.0		11.0	2.0
SN-MP ^{o**}	48.0		50.0	2.0
FMA°	39.0		41.0	2.0

CMF Sample Case

Question 2

Classification

Domain 4: Critical Analysis and Outcomes Assessment

Opening Scenario

A 16-year, 2-month-old female presents with the chief complaint that “My teeth stick out.”

Prompt

Describe the skeletal changes and your rationale for what occurred. Please respond in numbered list format below.

Model Responses

The board expects a fully proficient response for this question to include:

1. Decrease in SNB due to inadequate vertical control
2. Increase in ANB due to decrease in SNB (due to/as a result of inadequate vertical control)
3. Increase SN-MP due to inadequate vertical control
4. Increase in FMA due to inadequate vertical control

CMF Sample Case

Question 3

- The examinee will have access to the following records: Initial photo montage, initial intraoral photographs, initial lateral cephalogram, initial cephalometric tracing, and the pre-treatment dental analysis (see example below).

	PRE TX A
<u>1</u> TO NA mm	9.0
<u>1</u> TO SN°	111.0
- <u>1</u> TO NB mm	16.0
- <u>1</u> TO MP°	107.0

CMF Sample Case

Question 3

Classification

Domain 2: Treatment Objectives and Planning

Opening Scenario

A 16-year, 2-month-old female presents with the chief complaint that “My teeth stick out.”

Prompt

Identify appropriate dental treatment objectives for the variables in the case management table. Please respond in numbered list format below.

Model Responses

The board expects a fully proficient response for this question to include:

1. Retract maxillary incisors to NA
2. Retract mandibular incisors to NB
3. Decrease mandibular incisor proclination to MP
4. Decrease maxillary incisor proclination to SN

CMF Sample Case

Question 4

- The examinee will have access to the following records: Initial photo montage, initial intraoral photographs, initial lateral cephalogram, initial cephalometric tracing, final photo montage, final intraoral photographs, final lateral cephalogram, final cephalometric tracing, and the pre- /post-treatment dental analysis (see example below).

	PRE TX A	PROG A1	POST TX B	DIFF. A-B
<u>1</u> TO NA mm	9.0		-2.0	11.0
<u>1</u> TO SN°	111.0		77.0	34.0
- <u>1</u> TO NB mm	16.0		9.0	7.0
- <u>1</u> TO MP°	107.0		97.0	10.0

CMF Sample Case

Question 4

Classification

Domain 4: Critical Analysis and Outcomes Assessment

Opening Scenario

A 16-year, 2-month-old female presents with the chief complaint that “My teeth stick out.”

Prompt

Describe the changes in the maxillary and mandibular incisor position observed in this case. Please respond in numbered list format below.

Model Responses

The board expects a fully proficient response for this question to include:

1. Excessive retraction of maxillary incisors
2. Lack of torque control in maxillary incisors (resulting in retroclination of the maxillary incisors)
3. Retraction of mandibular incisors
4. Adequate torque control of mandibular incisors

Case Management Form

- Remember 3 planes of space
- Use precise and concise description
- Use appropriate terminology
- Treatment objectives and treatment plan should be in line with patient's needs not wants
- Actively participate in academic or study club case reviews

Superimpositions

Superimposition Sample Case

Examinees will be presented with a combination of the following case records, as needed:

- Initial photo montage
- Initial intraoral photographs
- Initial panoramic radiograph
- Initial lateral cephalogram
- Initial hand-wrist radiograph
- Final photo montage
- Final intraoral photographs
- Final panoramic radiograph
- Final lateral cephalogram
- Final superimpositions

Superimposition Sample Case

Question 1

Classification

Domain 4: Critical Analysis and Outcomes Assessment

Prompt

Assuming the time between initial and final records was 34 months, what dental changes occurred as a direct result of treatment? Please respond in numbered list format below.

Model Responses

The number of responses required to attain a fully proficient or borderline proficient score will depend on the changes that are observed in the superimposition relative to normal growth during the treatment interval.

Superimpositions

- Know radiographic analysis
- Review all 3 ABO superimposition videos (ABO website)
- Master superimposition interpretation skills
- Be able to differentiate changes from growth and treatment mechanics
- Read Buschang/Tadlock Guidelines for Assessing Growth and Development of the Orthodontic Patient. Seminars in Orthodontics, 2017